

European Society of Endocrinology clinical practice guidelines on the management of adrenal incidentalomas, in collaboration with the European Network for the Study of Adrenal Tumors

Martin Fassnacht,^{1,2,*} Stylianos Tsagarakis,³ Massimo Terzolo,⁴ Antoine Tabarin,⁵ Anju Sahdev,⁶ John Newell-Price,^{7,8} Iris Pelsma,⁹ Ljiljana Marina,¹⁰ Kerstin Lorenz,¹¹ Irina Bancos,¹² Wiebke Arlt,^{13,14} and Olaf M. Dekkers^{9,15}

¹Department of Internal Medicine I, Division of Endocrinology and Diabetes, University Hospital, University of Würzburg, Würzburg, Germany

²Comprehensive Cancer Center Mainfranken, University of Würzburg, Würzburg, Germany

³Department of Endocrinology, Diabetes and Metabolism, Evangelismos Hospital, Athens, Greece

⁴Internal Medicine 1, Department of Clinical and Biological Sciences, University of Turin, Turin, Italy

⁵Department of Endocrinology, Diabetes and nutrition, University and CHU of Bordeaux, Bordeaux, France

⁶Department of Imaging, St Bartholomew's Hospital, Barts Health, London, EC1A 7BE, United Kingdom

⁷Department of Oncology and Metabolism, Medical School, University of Sheffield, Sheffield, S10 2RX, United Kingdom

⁸Department of Endocrinology, Royal Hallamshire Hospital, Sheffield Teaching Hospitals NHS Foundation Trust, S10 2JF, United Kingdom

⁹Departments of Clinical Epidemiology and Internal Medicine, Leiden University Medical Centre, Leiden, The Netherlands

¹⁰Clinic for Endocrinology, Diabetes and Metabolic Diseases, University Clinical Centre of Serbia, Faculty of Medicine, University of Belgrade, Belgrade, Serbia

¹¹Department of Visceral, Vascular and Endocrine Surgery, Martin-Luther-University Halle-Wittenberg, Halle (Saale), Germany

¹²Division of Endocrinology, Metabolism, Nutrition and Diabetes, Mayo Clinic, Rochester, MN, United States

¹³Institute of Metabolism and Systems Research, University of Birmingham, Birmingham, B15 2TT, United Kingdom

¹⁴Centre for Endocrinology, Diabetes and Metabolism, Birmingham Health Partners, Birmingham, B15 2TH, United Kingdom

¹⁵Department of Clinical Epidemiology, Aarhus University, Aarhus, Denmark

*Corresponding author: Department of Endocrinology, University Hospital Würzburg, Oberdürrbacherstrasse 6, 97078 Würzburg, Germany. Email: fassnacht_m@ukw.de

Abstract

Adrenal incidentalomas are adrenal masses detected on imaging performed for reasons other than suspected adrenal disease. In most cases, adrenal incidentalomas are nonfunctioning adrenocortical adenomas but may also require therapeutic intervention including that for adrenocortical carcinoma, pheochromocytoma, hormone-producing adenoma, or metastases. Here, we provide a revision of the first international, interdisciplinary guidelines on incidentalomas. We followed the Grading of Recommendations Assessment, Development and Evaluation system and updated systematic reviews on 4 predefined clinical questions crucial for the management of incidentalomas: (1) How to assess risk of malignancy?; (2) How to define and manage mild autonomous cortisol secretion?; (3) Who should have surgical treatment and how should it be performed?; and (4) What follow-up is indicated if the adrenal incidentaloma is not surgically removed?

Selected Recommendations: (1) Each adrenal mass requires dedicated adrenal imaging. Recent advances now allow discrimination between risk categories: Homogeneous lesions with Hounsfield unit (HU) ≤ 10 on unenhanced CT are benign and do not require any additional imaging independent of size. All other patients should be discussed in a multidisciplinary expert meeting, but only lesions >4 cm that are inhomogeneous or have HU >20 have sufficiently high risk of malignancy that surgery will be the usual management of choice. (2) Every patient needs a thorough clinical and endocrine work-up to exclude hormone excess including the measurement of plasma or urinary metanephrines and a 1-mg overnight dexamethasone suppression test (applying a cutoff value of serum cortisol ≤ 50 nmol/L [≤ 1.8 $\mu\text{g/dL}$]). Recent studies have provided evidence that most patients without clinical signs of overt Cushing's syndrome but serum cortisol levels post dexamethasone >50 nmol/L (>1.8 $\mu\text{g/dL}$) harbor increased risk of morbidity and mortality. For this condition, we propose the term "mild autonomous cortisol secretion" (MACS). (3) All patients with MACS should be screened for potential cortisol-related comorbidities that are potentially attributable to cortisol (eg, hypertension and type 2 diabetes mellitus), to ensure these are appropriately treated. (4) In patients with MACS who also have relevant comorbidities surgical treatment should be considered in an individualized approach. (5) The appropriateness of surgical intervention should be guided by the likelihood of malignancy, the presence and degree of hormone excess, age, general health, and patient preference. We provide guidance on which surgical approach should be considered for adrenal masses with radiological findings suspicious of malignancy. (6) Surgery is not usually indicated in patients with an asymptomatic, nonfunctioning unilateral adrenal mass and obvious benign features on imaging studies. Furthermore, we offer recommendations for the follow-up of nonoperated patients, management of patients with bilateral incidentalomas, for patients with extra-adrenal malignancy and adrenal masses, and for young and elderly patients with adrenal incidentalomas. Finally, we suggest 10 important research questions for the future.

Keywords: adrenal tumors, diagnostic workup, therapy, follow-up

Received: May 16, 2023. Editorial Decision: May 31, 2023. Accepted: May 31, 2023

© The Author(s) 2023. Published by Oxford University Press on behalf of European Society of Endocrinology.

This is an Open Access article distributed under the terms of the Creative Commons Attribution License (<https://creativecommons.org/licenses/by/4.0/>), which permits unrestricted reuse, distribution, and reproduction in any medium, provided the original work is properly cited.

1. Summary of recommendations and highlighting the key changes in comparison to the guidelines 2016

The recommendations are worded as *recommend* (strong recommendation) and *suggest* (weak recommendation). The quality of evidence behind the recommendations is classified as very low (⊕○○○), low (⊕⊕○○), moderate (⊕⊕⊕○), and strong (⊕⊕⊕⊕). Recommendations based only on good practice or clinical experience of the panelists were not graded. See further Section 3.4.

1.1. General remarks

- R.1.1. We recommend that patients with adrenal incidentalomas are discussed in a multidisciplinary expert team meeting, if at least one of the following criteria is met:
 - Imaging is not consistent with a benign lesion.
 - There is evidence of hormone excess (including mild autonomous cortisol secretion [MACS] in patients with clinically relevant comorbidities potentially attributable to cortisol).
 - Adrenal surgery is considered.
 - Evidence of significant tumor growth during follow-up imaging.

The core multidisciplinary team should consist of a radiologist, an endocrinologist, and a surgeon, all with significant experience in the management of adrenal tumors.

1.2. Assessment of the risk of malignancy

- R.2.1 We recommend aiming to establish with the highest possible certainty if an adrenal mass is benign or malignant at the time of initial detection.
- R.2.2 We recommend that all adrenal incidentalomas undergo an imaging procedure to determine if the mass is homogeneous and lipid-rich and therefore benign (⊕⊕⊕○). For this purpose, we recommend the use of noncontrast CT as the first imaging modality if not yet performed (⊕⊕⊕○).
- R.2.3 We recommend that if the noncontrast CT is consistent with a benign adrenal mass (homogenous appearance and Hounsfield units [HU] ≤ 10), no further imaging is required (⊕⊕⊕○).
- R.2.4 If CT demonstrates a homogeneous adrenal mass with unenhanced HU between 11 and 20 and a tumor size < 4 cm, and the results of the hormonal work-up do not indicate significant hormone excess, we suggest an immediate additional imaging to avoid any follow-up imaging (⊕○○○). Alternatively, interval imaging in 12 months by noncontrast CT (or MRI) could be performed.
- R.2.5 If the adrenal mass is ≥ 4 cm and heterogeneous or has unenhanced HU > 20, there is a relevant risk that this lesion is malignant. Therefore, we suggest discussing such cases in a multidisciplinary team meeting. In most cases, immediate surgery will be the management of choice, but in some patients, additional imaging might be an option (⊕○○○). Prior to surgery, we suggest completely staging the patient (including at least thoracic CT and/or FDG-PET/CT [⊕○○○]). If surgery is not

performed, follow up imaging in 6-12 months is recommended (⊕○○○).

- R.2.6 In adrenal masses that do not fall in one of the categories above (eg, tumor size ≥ 4 cm with unenhanced HU 11-20; or tumor size < 4 cm with unenhanced HU > 20; or tumor size < 4 cm with heterogeneous appearance), we suggest an individualized approach with discussion in a multidisciplinary team meeting (⊕○○○). The likelihood of a malignant tumor is still low. Therefore, in most cases, immediate additional imaging according to the center expertise and availability is the preferred option. If the tumor is still judged as indeterminate mass and surgery is not performed, we recommend interval imaging in 6-12 months (noncontrast CT/MRI) (⊕○○○).
- R.2.7 We recommend against the use of an adrenal biopsy in the diagnostic work-up of patients with adrenal masses unless there is a history of extra-adrenal malignancy (see R.6.3.5).
- R.2.8 We suggest measurement of sex steroids and precursors of steroidogenesis (ideally using multisteroid profiling by tandem mass spectrometry) in patients in whom by imaging or clinical features an adrenocortical carcinoma is suspected (⊕⊕○○).

1.3. Assessment for hormone excess

- R.3.1 We recommend that every patient with an adrenal incidentaloma should undergo careful assessment including clinical examination for symptoms and signs of adrenal hormone excess.
- R.3.2 We recommend that patients with adrenal incidentalomas undergo a 1-mg overnight dexamethasone suppression test to exclude autonomous cortisol secretion (⊕⊕⊕○). In frail patients with limited life expectancy, this test may not be warranted.
- R.3.3 We recommend interpretation of the results of the 1-mg overnight dexamethasone test as a continuous rather than categorical (yes/no) variable (⊕○○○). However, we recommend using serum cortisol levels post dexamethasone ≤ 50 nmol/L (≤ 1.8 µg/dL) as a diagnostic criterion for the exclusion of autonomous cortisol secretion (⊕⊕○○).
- R.3.4 We recommend that in patients without signs and symptoms of overt Cushing's syndrome a postdexamethasone serum cortisol concentration above 50 nmol/L (> 1.8 µg/dL) should be considered as MACS without any further stratification based on the degree of cortisol nonsuppressibility (⊕⊕○○). In these patients, we recommend that ACTH-independency should be confirmed. Conditions that alter the results of the 1 mg DST should be considered for the interpretation of the results of the test. A repeat DST to confirm cortisol secretory autonomy is recommended. Additional biochemical tests to assess the degree of cortisol secretion might be useful. However, for clinical management the presence of comorbidities potentially attributable to cortisol excess, age, and the general condition of the patient are major factors for clinical decision-making.
- R.3.5 We recommend against considering patients with MACS (per definition without specific clinical signs of

Cushing's syndrome) as being at high risk for development of overt Cushing's syndrome (⊕⊕⊕○).

- R.3.6 We recommend screening patients with adrenal incidentaloma and MACS for hypertension and type 2 diabetes mellitus (⊕⊕○○) and suggest offering appropriate treatment of these conditions.
- R.3.7 We suggest screening patients with adrenal incidentaloma and MACS for vertebral fractures (⊕○○○) and to consider appropriate treatment of these conditions (⊕○○○).
- R.3.8 We recommend discussing the option of surgery with the patient who has MACS in addition to relevant comorbidities and a unilateral adrenal mass (⊕○○○). Age, sex, general health, degree and persistence of non-suppressible cortisol after dexamethasone, severity of comorbidities, and patient's preference should be taken into account (⊕○○○). In all cases, the proposal to perform surgery should be established within an expert multidisciplinary group.
- R.3.9 We recommend excluding pheochromocytoma by measurement of plasma free metanephrines or urinary fractionated metanephrines in all patients with adrenal lesions with features not typical for a benign adenoma.
- R.3.10 In patients with concomitant hypertension or unexplained hypokalemia, we recommend use of the aldosterone/renin ratio to evaluate primary aldosteronism.

1.4. Surgical treatment

- R.4.1 We recommend adrenalectomy as the standard of care for unilateral adrenal tumors with clinically significant hormone excess. In patients with MACS, surgery can be considered in patients with relevant co-morbidities, taking into account individual factors (detailed in R.3.8).
- R.4.2 We recommend against performing surgery in patients with an asymptomatic, nonfunctioning unilateral adrenal mass and obvious benign features on imaging studies (⊕⊕○○).
- R.4.3 If surgery is indicated for a benign adrenal mass causing hormone excess (including MACS), we recommend that a minimally invasive approach is used (⊕○○○).
- R.4.4 We suggest that minimally invasive adrenalectomy is performed by an expert high-volume adrenal surgeon in patients with unilateral adrenal masses with radiological findings suspicious of malignancy (R2.4-6) and a diameter ≤6 cm, but without evidence of local invasion (⊕○○○).
- R.4.5 We recommend open adrenalectomy is performed by an expert high-volume adrenal surgeon for unilateral adrenal masses with radiological findings suspicious of malignancy and signs of local invasion (⊕○○○).
- R.4.6 We recommend discussion of an individualized surgical approach by an expert high-volume adrenal surgeon in patients that do not fall in one of the above-mentioned categories in a multidisciplinary expert team meeting (⊕○○○).
- R.4.7 We recommend perioperative glucocorticoid treatment at surgical stress doses in all patients undergoing surgery and a preoperative morning serum cortisol

>50 nmol/L (1.8 μ/dL) after a 1 mg overnight dexamethasone test.

- R.4.8 We suggest that patients with MACS (similarly to patients with adrenal Cushing's syndrome) that underwent surgery should be followed by an endocrinologist until recovery of hypothalamic-pituitary-adrenal axis function has been documented.

1.5. Follow-up of patients not undergoing adrenal surgery after initial assessment

- R.5.1 We recommend against further imaging during follow-up in patients with an adrenal lesion with clear benign features on imaging studies (⊕⊕⊕○).
- R.5.2 In patients with an indeterminate adrenal mass (by imaging), opting not to undergo adrenalectomy following initial assessment, we suggest one repeat noncontrast CT or MRI after 6-12 months to exclude significant growth (⊕○○○). We suggest surgical resection if the lesion enlarges by more than 20% in maximum diameter (in addition to at least a 5 mm increase in maximum diameter) during this period. If there is growth of the lesion below this threshold, additional imaging again after 6-12 months might be considered.
- R.5.3 We recommend against repeated hormonal work-up in patients with hormonal work-up results within the reference range at initial evaluation unless new clinical signs of endocrine activity appear or there is worsening of comorbidities (eg, hypertension, type 2 diabetes) (⊕⊕○○).
- R.5.4 In patients with MACS, who do not undergo an adrenalectomy, we recommend only annual reassessment of comorbidities potentially attributable to cortisol (⊕⊕○○). For this purpose, we suggest that discharge from specialized endocrine follow-up be considered and that monitoring of comorbidities potentially attributable to cortisol could be undertaken by primary health care providers, if adequate surveillance for comorbidities is available in the community (⊕○○○). If these comorbidities develop or worsen, referral to an endocrinologist is suggested to reassess the endocrine status and reconsider the potential benefit of intervention.

1.6. Special circumstances

1.6.1. Patients with bilateral adrenal incidentalomas

- R.6.1.1 We recommend that for patients with bilateral or multiple adrenal masses each adrenal lesion is assessed individually at the time of initial detection according to the same imaging protocol as for unilateral adrenal masses to establish whether each nodule is benign or malignant.
- R.6.1.2 We recommend that all patients with bilateral adrenal incidentalomas should undergo clinical and hormonal assessment identical to that in patients with unilateral adrenal incidentaloma.
- R.6.1.3 We suggest approaching bilateral disease according to the following 4-option schema based on the results of the imaging and hormonal work-up (1) bilateral (macronodular) hyperplasia, (2) bilateral adrenal adenomas,

(3) 2 morphologically similar, but nonadenoma-like adrenal masses, and (4) 2 morphologically different adrenal masses. In patients who do not fall in one of these categories, an individualized management plan is needed.

- R.6.1.4 For patients with bilateral hyperplasia without autonomous cortisol secretion, we suggest measuring 17-hydroxyprogesterone to exclude congenital adrenal hyperplasia (CAH) due to 21-hydroxylase deficiency.
- R.6.1.5 For patients with bilateral (macronodular) hyperplasia or bilateral adenomas, we recommend assessment of comorbidities that are potentially attributable to MACS.
- R.6.1.6 In patients with bilateral metastases, lymphoma, infiltrative inflammatory disease, and hemorrhages, we recommend assessment for adrenal insufficiency.
- R.6.1.7 In patients with bilateral hyperplasia or bilateral adenomas and MACS, we suggest individualization of specific treatment options based on age, sex, degree of cortisol autonomy, general condition, comorbidities, and patient preference.
- R.6.1.8. We suggest against bilateral adrenalectomy in patients without clinical signs of overt Cushing's syndrome.

1.6.2 Adrenal incidentalomas in young or elderly patients

- R.6.2.1 We recommend urgent assessment of an adrenal mass in pregnant women and individuals <40 years of age because of a higher likelihood of malignancy as well as and clinically significant hormone excess.
- R.6.2.2 We suggest the use of MRI rather than CT in children, adolescents, and pregnant women if dedicated adrenal imaging is required.
- R.6.2.3 We suggest surgical resection if an adrenal mass is indeterminate on imaging in children, adolescents, pregnant women, and adults < 40 years of age.
- R.6.2.4 We recommend that investigation and management of patients with poor general health and a high degree of frailty be kept in proportion to potential clinical gain.

1.6.3. Patients with newly diagnosed adrenal mass and a history of extra-adrenal malignancy

- R.6.3.1 We recommend measurement of plasma or urinary metanephrines to exclude pheochromocytoma in patients with extra-adrenal malignancy with an indeterminate mass, even if the adrenal mass is likely to be a metastasis. We suggest additional hormonal work-up based on an individualized approach.
- R.6.3.2 We recommend that in patients with a history of extra-adrenal malignancy, adrenal lesions characterized as benign by noncontrast CT require no further specific adrenal imaging follow-up.
- R.6.3.3 In patients with a history of extra-adrenal malignancy, strong FDG uptake in the adrenal gland(s) on PET-CT is suggestive of metastasis. In case of moderate or no FDG uptake, further work-up with at least unenhanced CT is recommended.

- R.6.3.4 For indeterminate lesions in patients with a history of extra-adrenal malignancy, in whom the clinical management will be altered by the demonstration that the adrenal lesion is malignant, we suggest performing either an FDG-PET/CT (if not done already), surgical resection, or a biopsy (see also R.6.3.5). In all other patients, we recommend imaging follow-up at the same interval as imaging for the primary malignancy.
- R.6.3.5 We recommend that 3 key criteria be fulfilled before adrenal biopsy is considered: (1) the lesion is hormonally inactive (in particular, a pheochromocytoma has been excluded), (2) the lesion has not been conclusively characterized as benign by imaging, and (3) clinical management of the patient would be altered by knowledge of the histology.
- R.6.3.6 We recommend assessment of residual adrenal function in patients with large bilateral metastases.

1.8. Key changes between the guideline versions 2016 and 2023

See [Table 1](#).

2. Adrenal incidentaloma—clinical presentation and terminology

2.1 Definition, etiology, and epidemiology of adrenal incidentalomas

An adrenal incidentaloma is an adrenal mass detected on imaging not performed for a suspected adrenal disease. By this strict definition, the imaging study is not done for signs and symptoms potentially indicative of adrenal hormone excess (eg, pheochromocytoma, Cushing's, or Conn's syndrome) or an otherwise suspected adrenal disease, but rather for the evaluation of symptoms that are not suggestive of an adrenal problem, such as investigations for abdominal or back pain or for exclusion of pulmonary embolism or other lung disease. Conversely, discovery of an adrenal mass upon screening imaging in patients with a hereditary syndrome associated with an increased likelihood to develop adrenal tumors falls outside the definition of an adrenal incidentaloma. Similarly, adrenal masses discovered on imaging for tumor evaluation in extra-adrenal malignancies ("tumor staging" or follow-up) do not meet the strict definition of adrenal incidentaloma. However, as this is a clinically frequent scenario, we will address this in a specific section (see R.5.6.3).

The previous and current guidelines applied an arbitrary work-up threshold of 1 cm, because we and others consider that it is reasonable to perform additional diagnostic work-up only in adrenal masses \geq 1 cm, unless clinical signs and symptoms suggestive of adrenal hormone excess are present.

The etiology of adrenal incidentalomas varies and includes benign and malignant lesions derived from the adrenal cortex or medulla or masses of extra-adrenal origin ([Table 2](#)). Reported frequencies vary, depending on the context of the study and inclusion criteria. As expected, the prevalence of adrenal hormone excess in adrenal incidentaloma series originating from referral centers is much higher than those originating from unselected incidentaloma populations. Notably, the majority of patients with adrenal incidentalomas still do not undergo the recommended hormonal workup.¹

Table 1. Overview of key changes between the guidelines 2016 and 2023.

Guideline 2016	Guideline 2022 (relevant changes highlighted in bold)	Comments
R.2.2 We recommend that all adrenal incidentalomas undergo an imaging procedure to determine if the mass is homogeneous and lipid-rich and therefore benign (⊕○○○). For this purpose, we primarily recommend the use of noncontrast CT (⊕○○○).	R.2.2 We recommend that all adrenal incidentalomas undergo an imaging procedure to determine if the mass is homogeneous and lipid-rich and therefore benign (⊕⊕⊕○). For this purpose, we recommend the use of noncontrast CT as the first imaging modality if not yet performed (⊕⊕⊕○).	Increased level of incidence.
R.2.3 We suggest that if the noncontrast CT is consistent with a benign adrenal mass (HUs ≤ 10) that is homogeneous and smaller than 4 cm no further imaging is required (⊕○○○).	R.2.3 We recommend that if the noncontrast CT is consistent with a benign adrenal mass (homogenous appearance and HUs ≤ 10) no further imaging is required (⊕⊕⊕○).	Adapted criteria and increased the strength of recommendation and level of evidence.
R.2.4 If the adrenal mass is indeterminate on noncontrast CT and the results of the hormonal work-up do not indicate significant hormone excess, 3 options should be considered by a multidisciplinary team acknowledging the patient's clinical context: immediate additional imaging with another modality, interval imaging in 6-12 months (noncontrast CT or MRI), or surgery without further delay.	R.2.4 If CT demonstrates a homogeneous adrenal mass with unenhanced HU between 11 and 20 and a tumor size < 4 cm, and the results of the hormonal work-up do not indicate significant hormone excess, we suggest an immediate additional imaging to avoid any follow-up imaging (⊕○○○). Alternatively, interval imaging in 12 months by noncontrast CT (or MRI) could be performed.	Major modification.
	R.2.5 If the adrenal mass is ≥ 4 cm and heterogeneous or has unenhanced HU > 20, there is a relevant risk that this lesion is malignant. Therefore, we suggest discussing such cases in a multidisciplinary team meeting. In most cases, immediate surgery will be the management of choice, but in some patients, additional imaging might be an option (⊕○○○). Prior to surgery, we suggest completely staging the patient (including at least thoracic CT and/or FDG-PET/CT (⊕○○○)). If surgery is not performed, follow up imaging in 6-12 months is recommended (⊕○○○).	
	R.2.6 In adrenal masses that do not fall in one of the categories above (eg, tumor size ≥ 4 cm with unenhanced HU 11-20; or tumor size < 4 cm with unenhanced HU > 20; or tumor size < 4 cm with heterogeneous appearance), we suggest an individualized approach with discussion in a multidisciplinary team meeting (⊕○○○). The likelihood of a malignant tumor is still low. Therefore, In most cases, immediate additional imaging according to the center expertise and availability is the preferred option. If the tumor is still judged as indeterminate mass and surgery is not performed, we recommend interval imaging in 6-12 months (noncontrast CT/ MRI) (⊕○○○).	
R.3.2 We recommend that all patients with adrenal incidentalomas undergo a 1-mg overnight dexamethasone suppression test to exclude cortisol excess (⊕⊕○○).	R.3.2 We recommend that patients with adrenal incidentalomas undergo a 1-mg overnight dexamethasone suppression test to exclude autonomous cortisol secretion (⊕⊕⊕○). In frail patients with limited life expectancy, this test may not be warranted.	Increased level of evidence and added a statement on frail patients.
R.3.3 We suggest interpretation of the results of the 1-mg overnight dexamethasone test as a continuous rather than categorical (yes/no) variable (⊕○○○). However, we recommend using serum cortisol levels post dexamethasone ≤ 50 nmol/L (≤ 1.8 µg/dL) as a diagnostic criterion for the exclusion of autonomous cortisol secretion (⊕⊕○○).	R.3.3 We recommend interpretation of the results of the 1-mg overnight dexamethasone test as a continuous rather than categorical (yes/no) variable (⊕○○○). However, we recommend using serum cortisol levels post dexamethasone ≤ 50 nmol/L (≤ 1.8 µg/dL) as a diagnostic criterion for the exclusion of autonomous cortisol secretion (⊕⊕○○).	Increased the strength of recommendation.
R.3.4 We suggest that post dexamethasone serum cortisol levels between 51 and 138 nmol/L (1.9-5.0 µg/dL) should be considered as evidence of "possible autonomous cortisol secretion" and cortisol levels post dexamethasone > 138 nmol/L (> 5.0 µg/dL) should be taken as evidence of "autonomous cortisol secretion." Additional biochemical tests to confirm cortisol secretory autonomy and assess the degree of cortisol secretion might be required. However, for the clinical	R.3.4 We recommend that in patients without signs and symptoms of overt Cushing's syndrome a postdexamethasone serum cortisol concentration above 50 nmol/L (> 1.8 µg/dL) should be considered as MACS without any further stratification based on the degree of cortisol nonsuppressibility (⊕⊕○○). In these patients, we recommend that ACTH-independency should be confirmed. Conditions that alter the results of the 1 mg DST should considered for the interpretation of the results of the test. A repeat DST to confirm cortisol secretory autonomy is	Major modification.

(continued)

Table 1. Continued

Guideline 2016	Guideline 2022 (relevant changes highlighted in bold)	Comments
management the presence of potentially cortisol-related comorbidities and age of the patient are of major importance.	recommended. Additional biochemical tests to assess the degree of cortisol secretion might be useful. However, for clinical management the presence of comorbidities potentially attributable to cortisol excess, age, and the general condition of the patient are major factors for clinical decision-making.	
R.3.5 We recommend against considering “autonomous cortisol secretion” as a condition with a high risk for the development of overt Cushing’s syndrome (⊕⊕○○).	R.3.5 We recommend against considering patients with MACS (per definition without specific clinical signs of Cushing’s syndrome) as being at high risk for development of overt Cushing’s syndrome (⊕⊕⊕○).	Increased level of evidence.
R.3.6 We recommend screening patients with “possible autonomous cortisol secretion” or “autonomous cortisol secretion” for hypertension and type 2 diabetes mellitus (⊕○○○) and suggest offering appropriate treatment of these conditions.	R.3.6 We recommend screening patients with adrenal incidentaloma and MACS for hypertension and type 2 diabetes mellitus (⊕⊕○○) and suggest offering appropriate treatment of these conditions.	Increased level of evidence.
R.3.8 We suggest an individualized approach to consider patients with “autonomous cortisol secretion” due to a benign adrenal adenoma and comorbidities potentially related to cortisol excess for adrenal surgery (⊕○○○). Age, degree of cortisol excess, general health, comorbidities and patient’s preference should be taken into account. In all patients considered for surgery, ACTH-independency of cortisol excess should be confirmed.	R.3.8 We recommend discussing the option of surgery with the patient who has MACS in addition to relevant comorbidities and a unilateral adrenal mass (⊕○○○). Age, sex, general health, degree and persistence of nonsuppressible cortisol after dexamethasone, severity of comorbidities and patient’s preference should be taken into account (⊕○○○). In all cases, the proposal to perform surgery should be established within an expert multidisciplinary group.	Major modification.
R.3.9 We recommend excluding pheochromocytoma by measurement of plasma free metanephrines or urinary fractionated metanephrines.	R.3.9 We recommend excluding pheochromocytoma by measurement of plasma free metanephrines or urinary fractionated metanephrines in all patients with adrenal lesions with features not typical for a benign adenoma.	Restriction to a subset of patients.
R.3.11 We suggest measurement of sex hormones and steroid precursors in patients with clinical or imaging features suggestive of adrenocortical carcinoma.	R.2.7 We suggest measurement of sex steroids and precursors of steroidogenesis (ideally using multi-steroid profiling by tandem mass spectrometry) in patients in whom based on imaging or clinical features an adrenocortical carcinoma is suspected (⊕⊕○○).	Moved from section 5.3 to 5.2, slightly modified the text and provided evidence level.
R.4.2 We recommend against performing surgery in patients with an asymptomatic, nonfunctioning unilateral adrenal mass and obvious benign features on imaging studies (⊕○○○).	R.4.2 We recommend against performing surgery in patients with an asymptomatic, nonfunctioning unilateral adrenal mass and obvious benign features on imaging studies (⊕⊕○○).	Increased level of evidence.
	R.4.3 If surgery is indicated for a benign adrenal mass causing hormone excess (including MACS), we recommend that a minimally invasive approach is used (⊕○○○).	New recommendation.
R.4.3 We suggest performing laparoscopic adrenalectomy in patients with unilateral adrenal masses with radiological findings suspicious of malignancy and a diameter ≤ 6 cm, but without evidence of local invasion (⊕○○○).	R.4.4 We suggest that minimally invasive adrenalectomy is performed by an expert high-volume adrenal surgeon in patients with unilateral adrenal masses with radiological findings suspicious of malignancy (R2.4-6) and a diameter ≤ 6 cm, but without evidence of local invasion (⊕○○○).	Clarified language regarding minimally invasive adrenalectomy and added “expert high-volume adrenal surgeon.”
R.4.5 We suggest an individualized approach in patients that do not fall in one of the above-mentioned categories (⊕○○○).	R.4.6 We recommend discussion of an individualized surgical approach by an expert high-volume adrenal surgeon in patients that do not fall in one of the above-mentioned categories in a multidisciplinary expert team meeting (⊕○○○).	Increased the strength of recommendation and added “expert high-volume adrenal surgeon.”
	R.4.8 We suggest that patients with MACS (similarly to patients with adrenal Cushing’s syndrome) that underwent surgery should be followed by an endocrinologist until recovery of hypothalamic-pituitary-adrenal axis function has been documented.	New recommendation.
R.5.1 We suggest against further imaging for follow-up in patients with an adrenal mass < 4 cm with clear benign features on imaging studies (⊕○○○).	R.5.1 We recommend against further imaging during follow-up in patients with an adrenal lesion with clear benign features on imaging studies (⊕⊕⊕○).	Increased the strength of recommendation and level of evidence; skipped size cutoff.
R.5.3 We suggest against repeated hormonal work-up in patients with a normal hormonal	R.5.3 We recommend against repeated hormonal work-up in patients with hormonal work-up results	Increased the strength of

(continued)

Table 1. Continued

Guideline 2016	Guideline 2022 (relevant changes highlighted in bold)	Comments
work-up at initial evaluation unless new clinical signs of endocrine activity appear or there is worsening of comorbidities (eg, hypertension and type 2 diabetes) (⊕○○○).	within the reference range at initial evaluation unless new clinical signs of endocrine activity appear or there is worsening of comorbidities (eg, hypertension, type 2 diabetes) (⊕⊕○○).	recommendation and level of evidence.
R.5.4 In patients with “autonomous cortisol secretion” without signs of overt Cushing’s syndrome, we suggest annual clinical reassessment for cortisol excess comorbidities potentially related to cortisol excess (⊕○○○). Based on the outcome of this evaluation the potential benefit of surgery should be considered.	R.5.4 In patients with MAC, who do not undergo an adrenalectomy, we recommend only annual reassessment of comorbidities potentially attributable to cortisol (⊕⊕○○). For this purpose, we suggest that discharge from specialized endocrine follow-up be considered and that monitoring of comorbidities potentially attributable to cortisol could be undertaken by primary health care providers, if adequate surveillance for comorbidities is available in the community (⊕○○○). If these comorbidities develop or worsen, referral to an endocrinologist is suggested to reassess the endocrine status and reconsider the potential benefit of intervention.	Major modifications.
R.6.1.2 We recommend that all patients with bilateral adrenal incidentalomas should undergo clinical and hormonal assessment identical to that in patients with unilateral adrenal incidentaloma. The same applies for the assessment of comorbidities that might be related to autonomous cortisol secretion. In addition, 17-hydroxyprogesterone should be measured to exclude congenital adrenal hyperplasia, and testing for adrenal insufficiency should be considered, if suspected on clinical grounds or if imaging suggests bilateral infiltrative disease or hemorrhages.	R.6.1.2 We recommend that all patients with bilateral adrenal incidentalomas should undergo clinical and hormonal assessment identical to that in patients with unilateral adrenal incidentaloma. R.6.1.3 We suggest approaching bilateral disease according to the following 4-option schema based on the results of the imaging and hormonal work-up (i) bilateral (macronodular) hyperplasia, (ii) bilateral adrenal adenomas, (iii) 2 morphologically similar, but nonadenoma-like adrenal masses, (iv) 2 morphologically different adrenal masses. In patients who do not fall in one of these categories, an individualized management plan is needed. R.6.1.4 For patients with bilateral hyperplasia without autonomous cortisol secretion, we suggest measuring 17-hydroxyprogesterone to exclude congenital adrenal hyperplasia due to 21-hydroxylase deficiency. R.6.1.5 For patients with bilateral (macronodular) hyperplasia or bilateral adenomas, we recommend assessment of comorbidities that are potentially attributable to MACS. R.6.1.6 In patients with bilateral metastases, lymphoma, infiltrative inflammatory disease and hemorrhages, we recommend assessment for adrenal insufficiency.	Major modifications and new recommendations.
R.6.1.3 We suggest that for patients with bilateral incidentaloma the same recommendations regarding the indication for surgery and follow-up are used as for patients with unilateral adrenal incidentalomas.	R.6.1.7 In patients with bilateral hyperplasia or bilateral adenomas and MACS, we suggest individualization of specific treatment options based on age, sex, degree of cortisol autonomy, general condition, comorbidities and patient preference.	Major modifications.
R.6.1.4 We suggest that in patients with bilateral adrenal masses bilateral adrenalectomy is not performed for ACTH-independent “autonomous cortisol secretion” without clinical signs of overt Cushing’s syndrome. In selected patients, a unilateral adrenalectomy of the dominant lesion might be considered using an individualized approach considering age, degree of cortisol excess, general condition, comorbidities and patient preference.	R6.1.8. We suggest against bilateral adrenalectomy in patients without clinical signs of overt Cushing’s syndrome.	
	R.6.2.3 We suggest surgical resection if an adrenal mass is indeterminate on imaging in children, adolescents, pregnant women and adults < 40 years of age.	New recommendation.
R.6.3.4 For indeterminate lesions in patients with a history of extra-adrenal malignancy, we recommend imaging follow-up assessing the potential growth of the lesion at the same interval as imaging for the primary malignancy. Alternatively, FDG-PET/CT, surgical resection or a biopsy (see also R.6.3.5) can be considered.	R.6.3.4 For indeterminate lesions in patients with a history of extra-adrenal malignancy, in whom the clinical management will be altered by the demonstration that the adrenal lesion is malignant, we suggest performing either an FDG-PET/CT (if not done already), surgical resection or a biopsy (see also R.6.3.5). In all other patients, we recommend imaging follow-up at the same interval as imaging for the primary malignancy.	Emphasized subgroup of patients in whom alteration of management might occur.

Abbreviations: HU, Hounsfield unit; MACS, mild autonomous cortisol secretion.

Table 2. Etiology of adrenal tumors presented as adrenal incidentaloma.^a

Etiology	Prevalence of the different entities among adrenal incidentalomas
Adrenocortical adenoma or macronodular bilateral adrenal hyperplasia	80%-85%
• Nonfunctioning	40%-70%
• Mild autonomous cortisol secretion	20%-50%
• Primary aldosteronism	2%-5%
• Overt Cushing's syndrome	1%-4%
Other benign mass	
• Myelolipoma	3%-6%
• Cyst and pseudocyst	1%
• Ganglioneuroma	1%
• Schwannoma	<1%
• Hemorrhage	<1%
Pheochromocytoma	1%-5%
Adrenocortical carcinoma	0.4%-4%
Other malignant mass (mostly adrenal metastases)	3%-7%

^aBased on references¹⁻¹⁴ Due to different selection criteria and the fact that different studies used different definitions of hormone excess, the range of the reported prevalence is particularly wide. Furthermore, these studies might be highly susceptible to selection, referral and reporting bias.

The incidence and prevalence of adrenal masses can only be extrapolated from unselected imaging or autopsy studies. Autopsy studies suggest an overall prevalence of adrenal masses of around 2% (range 1.0%-8.7%), which increases with age.¹⁵⁻¹⁷ In a population study, the incidence of detected adrenal tumors was reported to increase 10-fold between 1995 and 2017, mainly representing adrenal incidentalomas, due to the growing number of the cross-sectional abdominal imaging scans in the population.¹ Radiological studies in patients report that prevalence of adrenal incidentalomas is around 3% in adults > 50 years and up to 10% in patients >80 years.¹⁵⁻²³ Estimates from the radiological studies have to be interpreted carefully due to the underlying imaging bias and potential underreporting.²⁴

In contrast to most imaging studies, a recent publication from China investigated healthy individuals who underwent abdominal CT imaging as part of a funded health check,² including 25 356 participants between age 18 and 78, with detection of an adrenal tumor in 351 (1.4%). The prevalence increased with age, from 0.2% in the youngest group (18-25 years) to 3.2% in those older than 65 years. In children, adrenal tumors are very rare and mostly not incidentalomas.¹

2.2. Remarks on terminology

As discussed above, the term “adrenal incidentaloma” can be defined by very restrictive criteria but is sometimes used in a much broader sense, referring to any adrenal mass. Therefore, in this guideline we frequently speak of adrenal masses or lesions. As an overarching term for an adrenal tumor that secretes hormones in an autonomous/unregulated manner we decided to use the term “functioning tumor.”

As indicated in Table 2, there is a substantial subset of patients with adrenal adenomas, in whom hypercortisolism can be detected during endocrine work-up, although these patients have no clinical signs or symptoms of Cushing's syndrome at presentation. In the 2016 European Society of

Endocrinology (ESE)-European Network for the Study of Adrenal Tumours (ENSAT) guidelines, we decided to avoid the terms “subclinical” or “preclinical” Cushing's syndrome to describe these patients, because there is strong evidence that this condition is quite different from overt Cushing's syndrome and that these patients very rarely develop overt Cushing's syndrome.^{19,25-32} In addition to common comorbidities like hypertension, obesity, and diabetes, overt Cushing's syndrome is usually associated with catabolic symptoms such as muscle weakness, skin fragility, osteoporosis, and comes with severe morbidity and clearly elevated mortality.³³⁻³⁷ Thus, we introduced the term “autonomous cortisol secretion,” which was widely used in publications of the last 7 years. These studies provided more evidence about the association of this condition and several metabolic comorbidities, as well as increased mortality (see below for details). Although we recognize that cortisol secretion may not be truly autonomous, being regulated by various aberrant hormone receptors, particularly in case of bilateral masses,³⁸ we consider the term autonomous as indicative that cortisol secretion is not under the physiological control of the hypothalamic-pituitary axis.

In the 2016 guidelines, we discriminated between “autonomous cortisol secretion” (defined by cortisol after 1 mg DST > 5.0 µg/dL) and “possible autonomous cortisol secretion” (cortisol after 1 mg DST 1.9-5.0 µg/dL). However, recent studies suggested that also the category “possible autonomous cortisol secretion” is associated with an increased morbidity and mortality^{12,39,40} and therefore we have removed this distinction.

Due to the fact that the term “autonomous cortisol secretion” might include also patients with overt Cushing syndrome, we now decided to add the word “mild” before autonomous cortisol secretion and use the abbreviation MACS throughout the recommendations.

2.3. Short overview on adrenal imaging

For the differentiation of malignant from benign adrenal tumors there are still 3 main imaging techniques in mainstream clinical use: CT, MRI, and positron emission tomography with [¹⁸F]2-deoxy-D-glucose (mostly combined with CT; FDG-PET/CT). CT and MRI are techniques mainly aiming to identify benign lesions, therefore representing tools designed for the exclusion of adrenal malignancy.^{1,8,41-44} Conversely, FDG-PET/CT is mainly used for the detection of malignant disease.⁴⁵⁻⁵²

CT has a high spatial and quantitative contrast resolution, which allows assessment of tissue density by measuring X-ray absorption of tissues. This allows calculation of tissue attenuation or tissue density values, which are measured in HUs and quantify X-ray absorption of tissues compared to water, which is conventionally allocated a HU value of 0. **Noncontrast (or “unenhanced”)** CT is currently the most reliable imaging tool for adrenal tumors (see details below, Section 4.1.1).

Standard **contrast-enhanced** CT is usually not helpful to discriminate benign from malignant adrenal tumors. However, CT with a delayed washout analysis is suggested for this purpose. Typically, adenomas take up intravenous CT contrast rapidly, but also have a rapid loss of contrast—a phenomenon termed “contrast enhancement washout.” Malignant adrenal lesions usually enhance rapidly but demonstrate a slower washout of contrast medium. This washout phenomenon

can be quantified by “contrast washout values,” which involve lesion attenuation measurements at specific time points acquired in a dedicated adrenal CT: prior to injection of contrast medium (HU_{nativ}), at 60 seconds following injection of contrast medium (HU_{max}) and then at 10 or 15 minutes after contrast injection. This allows calculation of the relative contrast enhancement washout ($=100 \times [HU_{\text{max}} - HU_{10/15\text{min}}]/HU_{\text{max}}$) and absolute contrast enhancement washout ($=100 \times [HU_{\text{max}} - HU_{10/15\text{min}}]/[HU_{\text{max}} - HU_{\text{nativ}}]$). Details about the most suitable cutoffs are provided in Section 4.1.1.

MRI is a nonionizing radiation-based imaging modality utilizing weak radio wave signals emitted by body tissues when the body is placed in a strong magnetic field and radio frequency pulses are applied. The advantages of MRI over CT are its lack of radiation exposure, lack of iodine-based contrast media, and its superior tissue contrast resolution. Longer scanning times, claustrophobia, and in-situ MRI incompatible devices are the main disadvantages of MRI. For the differentiation of benign and malignant adrenal masses the MRI technique of **chemical-shift imaging** is most commonly used.^{53–58} Chemical shift imaging relies on the fact that, within magnetic fields, protons in water vibrate at a slightly different frequency than protons in lipid. As a result, water and fat protons oscillate in and out of phase with respect to one another. Adrenal adenomas with a high content of intracellular lipid usually lose signal intensity on out-of-phase images compared to in-phase images, whereas malignant lesions and pheochromocytomas (but also some lipid-poor adrenal adenomas) that lack intracellular lipid remain unchanged and retain their signal.^{41,57,59} MR signal intensity units are arbitrary units, unlike CT, and therefore are subject to numerous technical variations. Simple visual assessment of signal intensity loss is diagnostic in most cases, reserving quantitative methods to less clear-cut cases. Quantitative analysis can be made using the adrenal-to-spleen signal ratio and the signal intensity index.

^{18}F FDG-PET is a nuclear medicine modality that provides quantitative tomographic images after intravenous injection of a beta plus (positron)-radiation emitting radiotracer (18-fluorine) used to label 2-deoxy-D-glucose rendering Fluoro-DeoxyGlucose (^{18}F FDG). Both glucose and deoxyglucose enter cells via transmembrane glucose transporters and undergo phosphorylation but while glucose undergoes further enzymatic breakdown, deoxyglucose becomes trapped in intracellular compartments. Cancer cells have an increased requirement for glucose and, therefore, take up more glucose and deoxyglucose than normal cells.⁶⁰ However, FDG is not a specific marker for cancer cells but a marker only for increased glucose metabolism. Thus, uptake can also be increased in cells with an increased energy requirement due to conditions other than cancer, for example, active infection. Quantitative measurement of ^{18}F concentrations within tissues provides the most commonly used clinical measurement index, standard uptake value (SUV), which compares the intensity of uptake of ^{18}F in the adrenal lesion to the average uptake of whole body. Standard uptake value values have been utilized to differentiate between benign from malignant adrenal lesions. FDG-PET alone has a high sensitivity for detection of metabolic changes but its spatial resolution for anatomical localization is poor. The solution is a hardware fusion between PET and CT (PET/CT) allowing simultaneous acquisition of PET and CT data. In clinical practice, this involves injecting patients with FDG tracers at least 1 hour prior

to the start of combined PET/CT. In addition to its diagnostic potential to discriminate between benign from malignant adrenal lesions, FDG-PET/CT can help—in case of a suspected adrenocortical carcinoma or pheochromocytoma—to identify metastases, and—in case suspected adrenal metastases—to detect the primary tumor.

Other potentially emerging imaging techniques (eg, metomidate-based adrenal imaging) are not yet clinically widely available and, therefore, will not be considered in this guideline.

2.4. Remarks on the difficulties with hormonal testing

Hormone assessment is crucial in the context of the work-up for an adrenal incidentaloma. Several pitfalls have to be considered (eg, daily rhythm, sex-/age-dependency, limitations of assays, drug interactions, preanalytic difficulties). Furthermore, normal ranges vary substantially, depending on the method used, so it is essential to interpret test results in the context of the appropriate reference range. We refer to other guidelines that have addressed these issues in more detail.^{61–64}

3. Methods

3.1. Guideline working group

This guideline was developed by the ESE in collaboration with the ENSAT. The chairs of the guideline panel Martin Fassnacht (clinical) and Olaf Dekkers (methodology) were appointed by the ESE Clinical Committee. The other members were suggested by the chairs and approved by the Clinical Committee of ESE: endocrinologists (Wiebke Arlt [United Kingdom], Irina Bancos [United States], Ljiljana Marina [Serbia], John Newell-Price [United Kingdom], Antoine Tabarin [France], Massimo Terzolo [Italy], Stylianos Tsagarakis [Greece]), a radiologist (Anju Sahdev [United Kingdom]), an endocrine surgeon (Kerstin Lorenz [Germany]), and another methodologist (Iris Pelsma [The Netherlands]). Ljiljana Marina served as representative of the ESE Young Endocrinologists and Scientists and John Newell-Price as representative of the *Endocrine Society*. The systematic literature search was performed by Iris Pelsma supervised by Olaf Dekkers. The working group had several virtual meetings between September 2021 and April 2023 and 1 in-person meeting in October. Consensus was reached upon discussion; minority positions were taken into account in the Reasoning behind recommendations. Prior to the process, all participants completed conflict of interest forms (see Table S1).

3.2 Target group

This guideline was developed for healthcare providers of patients with adrenal incidentalomas, that is, endocrinologists, radiologists, surgeons, and specialists in internal medicine. However, general practitioners might also find the guideline useful, as might our patients. In addition, the guideline document can serve as guidance for patient information leaflets. A draft of the guideline was reviewed by 3 experts in the field (see “Acknowledgment” section) and the endorsing societies (see Section 3.3) and has been submitted for comments to all members of ESE and ENSAT. All comments and suggestions were

subsequently discussed and implemented as appropriate by the panel (see [Table S2](#)).

3.3 Endorsement by other societies

To achieve wide acceptance of the guidelines within the clinical community of the different disciplines involved in the management of adrenal incidentalomas, the draft of these guideline document was submitted to several other professional/learned societies. Finally, the following societies endorsed the presented guidelines: the Endocrine Society, the European Society of Urogenital Radiology, and the Society of Abdominal Radiology.

3.4 Aims

The overall purpose of this guideline is to provide clinicians with practical guidance for the management of patients with adrenal incidentalomas.

3.5 Summary of methods used for guideline development

This guideline is a revision of the 2016 guideline.⁶⁵ The panel first decided which parts of the guideline were in need of revision and which clinical questions needed an updated literature search (see Section 3.6).

The methods used for ESE guidelines have been described in more detail previously.⁶⁶ In short, the guideline used GRADE (Grading of Recommendations Assessment, Development and Evaluation) as a methodological base. The first step was to define the clinical question(s) (see Section 3.6), the second a systematic literature search (see Section 3.7). After including relevant articles, we (1) estimated an average effect (or other measure such as incidence, diagnostic accuracy, etc.) for specific outcomes (if possible), and (2) rated the quality of the evidence. The quality of evidence is classified as low very low (⊕○○○), low (⊕⊕○○), moderate (⊕⊕⊕○), and strong (⊕⊕⊕⊕).

For the recommendations we considered: (1) quality of the evidence, (2) balance of desirable and undesirable outcomes, and (3) values and preferences (patient preferences, goals for health, costs, management inconvenience, feasibility of implementation, etc.).^{24,67} The recommendations are worded as *recommend* (strong recommendation) and *suggest* (weak recommendation). Formal evidence syntheses were performed and graded only for recommendations addressing our initial questions. Recommendations based only on good practice or clinical experience of the panelists were not graded.⁶⁸ Recommendations were derived from majority consensus of the guideline panel, but if members had substantive disagreements, this is acknowledged in the manuscript. All recommendations are accompanied by text explaining the rationale of specific recommendations.

3.6. Clinical question, eligibility criteria, and endpoint definition

At the beginning of the guideline development process in 2014 and for this revision in 2021, the panel agreed on the 4 most important clinical questions in the management of patients with adrenal incidentalomas ([Table 3](#)), for which a detailed literature search was subsequently performed. A new clinical question (1c) regarding the diagnostic value of steroid

profiling was added. Questions 2a and 2b were addressed in a separate systematic review⁶⁹ and are summarized in his guideline.

3.7 Description of search and selection of literature

A literature search in electronic medical databases was originally performed for all 4 clinical questions for the guideline in 2016.⁶⁵ For all questions, the search was updated, and the same databases were searched until July 2022 (Questions 3, 4), August 2022 (Questions 1a, 2), and November 2022 (Question 1b). A new systematic search (until August 2022) was added for studies on the diagnostic value of steroid profiling (1c). Details on the search strategy and the used databases are provided in [Table S3](#). Summaries of included papers and evidence tables are provided in [Tables S4-S15](#).

For all predefined clinical questions details of the yield of the search are shown in [Table 3](#). In summary, we included 60 (20 new) studies for clinical Question 1 (CT 7, MRI 5, PET-CT 6, biopsy 40, steroid profiling 2); 46 (34 new) studies for clinical Question 2a (biochemical profile in adrenal incidentaloma); 11 studies (7 new) for clinical Question 2b (therapeutic approaches for patients with MACS); 14 (5 new) studies for Question 3 (surgery); and 29 (18 new) studies, one being a systematic review, for clinical Question 4 (follow-up).

4. Summary and conclusions from systematic reviews

4.1 Assessment of the risk of malignancy (Question 1)

4.1.1 Assessment of the risk of malignancy: imaging (Question 1a)

All studies of CT, MRI, or FDG-PET in adults were considered eligible if included patients underwent imaging for any indications other than investigation of suspected adrenal mass and index imaging test characteristics were reported.

No randomized studies comparing imaging tests were identified. Risk of bias ranged from low to high, with the majority having unclear or high risk of bias (mainly due to unclear population selection, retrospective selection of the diagnostic threshold and/or inadequate reference standards).

Four commonly used diagnostic thresholds were studied: (1) tumor density > 10 HU and > 20 HU on noncontrast CT; (2) CT with delayed contrast media washout: absolute percentage washout and/or relative percentage washout at any washout percentage or delay time on enhanced CT; (3) MRI chemical shift analysis: loss of signal intensity between in and out of phase images (including both qualitative and quantitative estimates of signal loss); and (4) FDG-PET or PET-CT: maximum SUV (SUVmax) or the ratio of SUVmax in the adrenal mass compared to the liver (adrenal liver ratio).

Overall, for incidentally discovered adrenal lesions, estimates of test performance are still based on a small number of studies. Only very few included patients with definitive diagnoses, thereby making it difficult to discern whether any imaging modality performs better than alternatives.

CT. We aimed to include studies that assessed diagnostic accuracy measures for the distinction of benign versus malignant adrenal lesions (adrenocortical carcinoma as well as other malignancies) ([Figure 1](#); [Tables S4 and S5](#)). Studies that assessed accuracy measures only for the distinction adrenocortical

Table 3. Overview of the key clinical questions and predefined outcome parameters.

Clinical question	Predefined selection criteria and key outcome parameters ^a	Metrics of the literature search
<p>Question 1a) What is the most accurate diagnostic imaging procedure to determine whether an adrenal mass is benign in patients with unilateral or bilateral adrenal mass(es) on imaging with or without history of other malignant lesions?</p>	<ul style="list-style-type: none"> • Studies on imaging in patients with incidentally discovered adrenal mass(es), including patients undergoing staging for known extra-adrenal malignancy. • Sample size > 10 patients and <20% pheochromocytomas in total cohort • Diagnostic intervention: CT (noncontrast, contrast-enhanced, washout), MRI, FDG PET(CT), for specific imaging characteristics data in > 60% of patients • Reference standard: > 50% had histology or imaging-guided follow-up • Reporting 2 × 2 contingency table data or at least 2 indices of diagnostic accuracy (sensitivity, specificity, negative or positive predictive value) and disease prevalence. 	<ul style="list-style-type: none"> • 1315 abstracts • 49 potentially relevant articles • 18 (including 10 new) studies included in systematic review and meta-analysis • Reasons for exclusion of articles were lack of test accuracy data, inadequate or unclear reference standard and ineligible populations.
<p>Question 1b) What is the diagnostic accuracy of adrenal biopsy?</p>	<ul style="list-style-type: none"> • Studies on patients with adrenal masses undergoing an adrenal biopsy procedure • Outcomes: nondiagnostic rate, diagnostic accuracy data, complication rate • For studies included in the diagnostic accuracy analysis: 1) Reference standard: at least 50% of population either histology from adrenalectomy or autopsy, imaging follow up 3-12 months or clinical follow up of 2 years and 2) reporting 2 × 2 contingency table data or at least 2 indices of diagnostic accuracy (sensitivity, specificity, negative or positive predictive value) and disease prevalence. 	<ul style="list-style-type: none"> • 367 abstracts • 40 studies (8 new) included in systematic review of at least one outcome. • Diagnostic accuracy data included from 11 studies (3 new) • Major reasons for exclusion overall were: no outcomes of interest, fewer than 10 patients, abstract only, patient overlap. • Major exclusions from diagnostic accuracy analysis were: suboptimal reference standard and >30% nonadenomas
<p>Question 1c) What is the diagnostic accuracy of urine and plasma steroid profile?</p>	<ul style="list-style-type: none"> • Studies on patients with adrenal masses undergoing steroid profiling to determine if the adrenal mass is malignant or not. • Sample size > 10 patients and <20% pheochromocytomas in total cohort • Reference standard: > 50% had histology or imaging-guided follow-up • Reporting 2 × 2 contingency table data or at least 2 indices of diagnostic accuracy (sensitivity, specificity, negative or positive predictive value) and disease prevalence. • See⁶⁹ for details 	<ul style="list-style-type: none"> • 367 abstracts • 23 potentially relevant articles • 2 studies included in systematic review and meta-analysis • Reasons for exclusion of articles were lack of test accuracy data.
<p>Question 2a) Is glucocorticoid excess associated with an increased cardiovascular, metabolic and fracture risk in patients with adrenal mass(es), in patients with an AI where endocrine work-up for was performed?</p>	<ul style="list-style-type: none"> • See⁶⁹ for details 	<ul style="list-style-type: none"> • 46 (34 new) studies included • See⁶⁹ for details
<p>Question 2b) Should surgery or a conservative/medical approach be recommended in patients with adrenal mass(es) and with defined biochemistry and cardiovascular, metabolic and fracture risk potentially indicative of mild glucocorticoid excess?</p>	<ul style="list-style-type: none"> • See⁶⁹ for details 	<ul style="list-style-type: none"> • 11 (7 new) studies are included • See⁶⁹ for details
<p>Question 3) Should minimally invasive (including laparoscopic and retroperitoneoscopic) or open surgery be used for patients with nonmetastatic adrenal masses suspected to be malignant?</p>	<ul style="list-style-type: none"> • Original studies on adults with suspected nonmetastatic adrenocortical carcinoma • Comparison between minimally invasive versus open surgery • Reporting at least one of the crucial outcomes: perioperative morbidity and mortality; completeness of resection; recurrence-free and overall survival; pain or patient satisfaction • Publications with less than 10 patients per study arm were excluded. 	<ul style="list-style-type: none"> • 690 abstracts (313 new) • 38 potentially relevant articles (25 new) • 3 excluded due to samples size < 10 patients per arm, 1 excluded as review • 14 (5 new) studies included

(continued)

Table 3. Continued

Clinical question	Predefined selection criteria and key outcome parameters ^a	Metrics of the literature search
<p>Question 4) What is the optimal follow-up in patients with an apparently benign adrenal incidentaloma in order to detect malignant transformation and/or development of overt hormone excess?</p>	<ul style="list-style-type: none"> • Original studies on patients with an adrenal mass without hormone excess and no clear evidence of malignant adrenal tumor at time of primary diagnosis • Reporting at least one of the following outcomes: malignancy in the adrenal (any kind); development of clinically relevant overt hormone excess (Cushing's syndrome, pheochromocytoma, primary hyperaldosteronism) 	<ul style="list-style-type: none"> • 516 abstracts (383 new) • 59 potentially relevant articles (40 new) • Overlapping with previous search ($n = 2$), 9 excluded due to overlapping population ($n = 3$), not relevant to question ($n = 3$), not available in full-text ($n = 2$), unclear methods ($n = 1$) • 1 systematic review of 14 studies and 28 additional cohort studies (18 new) included

^aThe updated systematic review was performed for publication: July 2022 (Q1a, 1c, 2, Q3, 4), and November 2022 (Q1b), respectively.

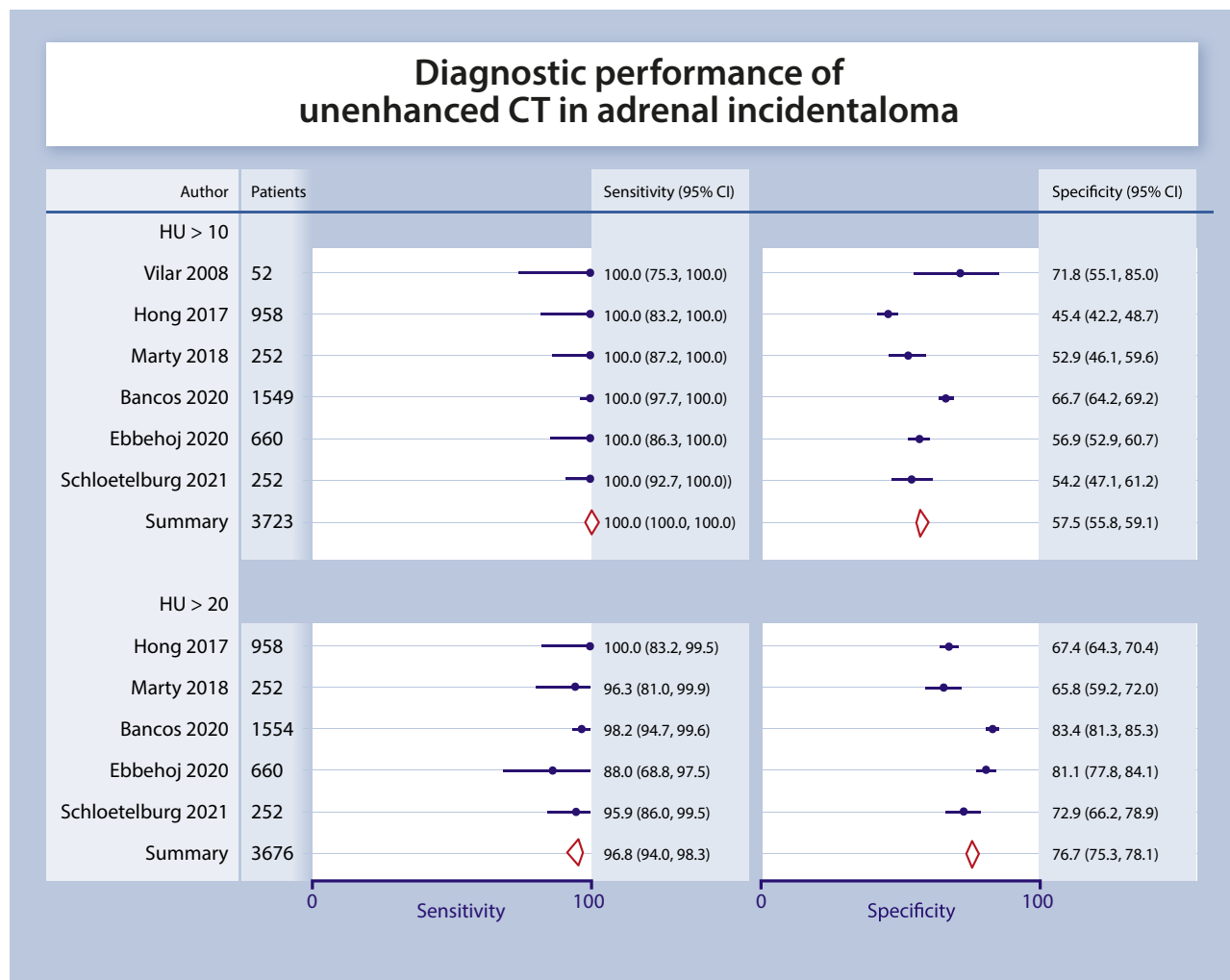


Figure 1. Diagnostic performance of unenhanced CT in adrenal incidentaloma. Sensitivity indicates if malignant tumors are correctly identified, whereas as specificity refers to correct identification of benign lesions.

carcinoma—versus other lesions,⁷⁰ or adenomas versus other lesions⁷¹—were not included.

Five studies including 4752 patients who underwent unenhanced CT imaging reported data on the value of the 4 cm size cutoff to distinguish benign from malignant lesions.^{1,8,44,72,73} Reported sensitivities ranged from 23%¹ to 90%;⁴⁴ the pooled sensitivity was 77% (95% CI 45%-93%). The pooled specificity was 90% (95% CI 78%-96%) (Figure S1).

Unenhanced CT. Six studies (including five from the new search) reported diagnostic accuracy data for the distinction benign/malignant using HUs for the attenuation value on unenhanced CT.^{1,8,44,72-74} CT density >10 HU has a very high sensitivity for detection of adrenal malignancy: 100% in all 6 studies, 95% CI 100%-100%; meaning that adrenal masses with a density of ≤10 HU are virtually never malignant. The pooled specificity was clearly lower (58%, 95% CI 56%-59%), meaning a large number of benign lesions had HU > 10. Five studies provided data for the HU > 20 cutoff and the pooled sensitivity was still high (97%, 95% CI 94%-98%). However, up to 7% of metastases had a HU between 10 and 20^{1,8,44,72} (Figure 1).

Washout-CT. Washout (absolute and relative) in a true incidentaloma population was studied only in 3 studies.^{72,73,75} However, the study from France was not included as washout data were studied in <50% of patients.⁷³ Notably, while a cutoff of 60% for absolute washout and cutoff of 40% for relative washout are often suggested (including in our previous guidelines),⁶⁵ evidence for accuracy of these cutoffs in adrenal incidentalomas was very low.⁷⁶ A recent study demonstrated that with these cutoffs 22% (using absolute washout) and 8% (relative washout) of malignant tumors, respectively, were not correctly identified.⁷² To detect all malignant tumors, a cutoff of 58% for relative percentage washout was suggested leading to a specificity of only 15%. However, this suggested cutoff is in clear need of external validation. There is also some uncertainty about the best timing of the delayed imaging and no properly designed study comparing different time points. However, there are no doubts that at least a 10 minutes delay is required and 15 minutes might be even better.

MRI. No new studies reporting on diagnostic accuracy for MRI were found based on the 2022 search update; it should be noted that the technique is well established. For the confirmation of benign tumors in true adrenal incidentalomas, 2 of 3 MRI studies including 150 patients reported slightly lower sensitivity and specificity than CT using of adrenal-liver and adrenal-spleen ratios and loss of signal intensity.⁷⁷⁻⁷⁹ Four of the five studies of MRI investigating patients with history of extra-adrenal malignancy used 1.5 Tesla scanners and reported high sensitivity (89%-99%) for measures of adrenal-liver, adrenal-spleen, adrenal-muscle ratios, and loss of signal intensity.^{53,80-82} Specificity varied (60%-93%) but was high for most MRI measures.⁷⁶

PET. The performance of PET for adrenal liver ratio and SUVmax measures was assessed in 6 studies (2 included in the previous guideline);^{49,51,52,83-85} 1 study provided accuracy data for 2 different cutoffs (Figure 2; Tables S4 and S5).⁴⁹ Different cutoffs were used with adrenal liver ratio and

SUVmax hampering a robust estimation of diagnostic accuracy measures; therefore we did not perform a formal meta-analysis. For SUVmax, reported sensitivities ranged from 87%⁸³ to 100%.⁸⁴ For adrenal liver ratio, reported sensitivities were similar and ranged from 85%⁵¹ to 100%.⁸⁴ Reported specificities were lower (Figure 2).

4.1.2 Diagnostic value of adrenal biopsy (Question 1b)

Data on the diagnostic accuracy, complications and nondiagnostic rates were previously synthesized in a systematic review that included 32 studies.⁸⁶ In this systematic review, studies had diverse population inclusion criteria, reference standards and biopsy techniques. The pooled nondiagnostic rate (30 studies, 2030 adrenal biopsy procedures) was 8.6% (95% CI 6.1%-11%). The pooled overall complication rate 2.4% (1.5%-3.3%), although this is likely an underrepresentation due to differences in both assessment and reporting of complications as well as the retrospective nature of the studies. Performance of adrenal biopsy in the diagnosis of malignancy was (8 studies, 323 biopsies): sensitivity 87% (78%-93%) and specificity 100% (76%-100%). Performance was lower (and with even wider 95% CIs) for adrenocortical carcinoma: sensitivity 70% (42%-88%) and specificity 98% (86%-100%).

Since the systematic review published in 2016, a database search using similar criteria found additional eight studies⁸⁷⁻⁹⁴ that reported on nondiagnostic biopsy rates (2032 patients, pooled diagnostic rate of 5.8%), 3 studies^{87,88,91} reporting on complications (896 patients, mean complication rate of 1.7%), and 3 studies^{87,88,94} reporting on the diagnostic accuracy of either CT-guided adrenal biopsy (sensitivity of 88.5%, specificity of 91.5%, positive predictive value of 93.4%, and negative predictive value of 85.5%) or endoscopic ultrasound-guided adrenal fine needle aspiration (sensitivity of 89%-100%, specificity of 97%-100%, positive predictive value of 89%-92%, and negative predictive value of 94%-100%). Overall, diagnostic accuracy, nondiagnostic and complication rates were similar to the systematic review from 2016.

4.1.3 Diagnostic value of steroid profiling (Question 1c)

In recent years, several studies have investigated steroid profiling as a tool to discriminate benign from malignant adrenal tumors (Tables S6 and S7).^{8,95-100} However, only 2 studies focused on incidentalomas and reported diagnostic accuracy measures for steroid profiles, to assess malignancy risk. A large prospective study ($n = 2017$), employed urine steroid metabolomics, combining urine steroid profiling by tandem mass spectrometry with machine learning-based steroid data analysis,⁸ validating a machine learning algorithm previously determined in a proof-of-principle study.⁹⁵ One single retrospective study ($n = 577$) used plasma steroid profiling by tandem mass spectrometry in a cohort of incidentaloma.¹⁰⁰ As a stand-alone test, the sensitivity was not high enough (about 80%) for both urine and plasma steroid profiling approaches to rule out malignancy with certainty. However, when combined with the imaging criteria (size >4 cm and HU > 20), urine steroid metabolomics diagnosed adrenocortical carcinoma (but not other malignancy) with accuracy higher than imaging alone.⁸

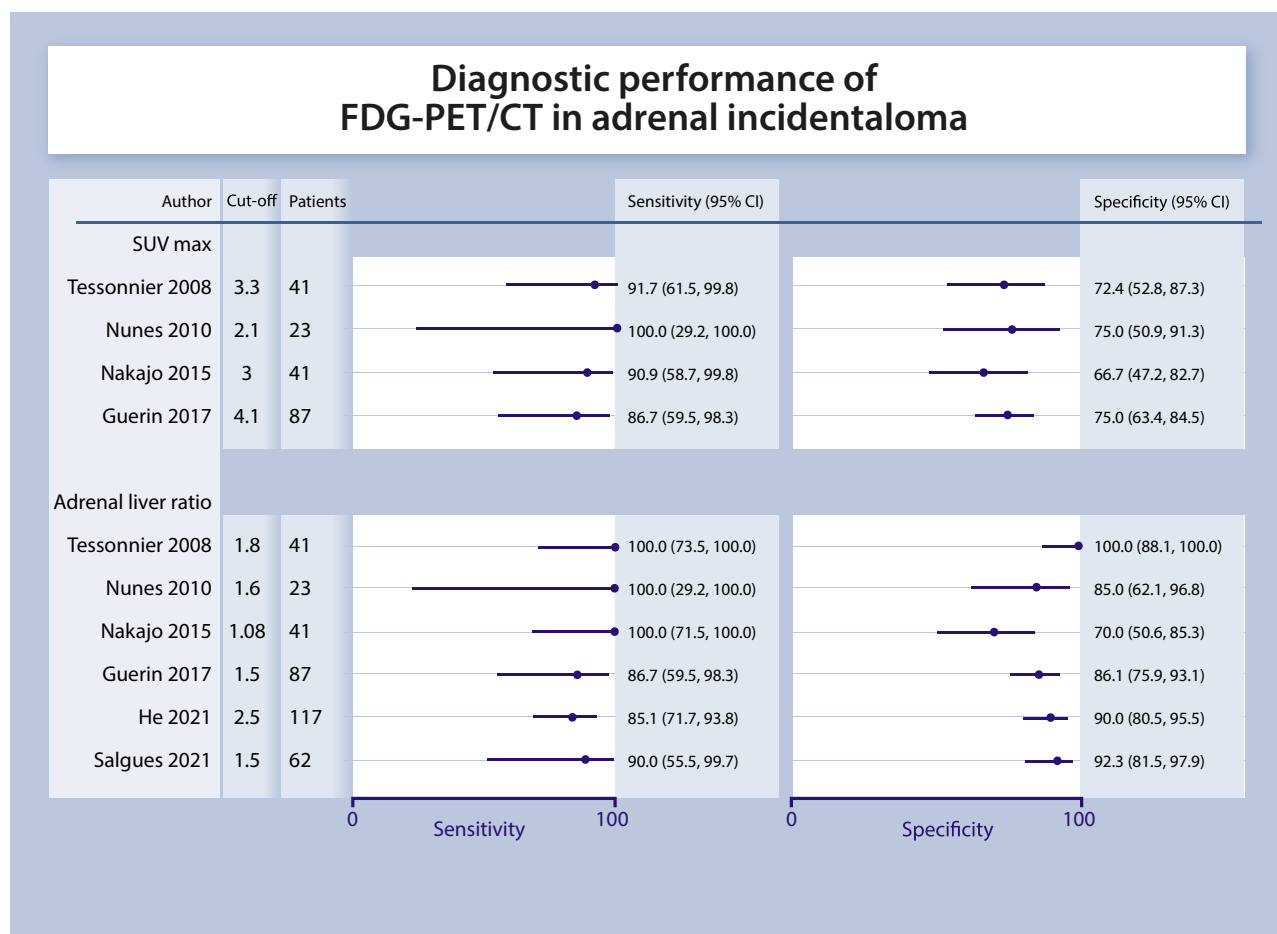


Figure 2. Diagnostic performance of FDG-PET/CT in adrenal incidentaloma. Sensitivity indicates if malignant tumors are correctly identified, whereas as specificity refers to the correct identification of benign lesions. Due to the different cutoffs used in these studies, we abstained from providing pooled values.

4.2 Mild autonomous cortisol secretion in adrenal incidentalomas: comorbidities and effect of treatment

Forty-six (34 new) studies for clinical question 2a (biochemical profile in adrenal incidentaloma),^{12,39,40,101-142} and 11 (7 new) studies were assessed for clinical question 2b (therapeutic approaches for patients with MACS). See⁶⁹ for details.

4.2.1 Assessment of MACS in relation to clinical outcomes (Question 2a)

In summary, prevalence of cardiovascular risk factors was higher in patients with MACS (Figure 3; Tables S8 and S9). Prevalence of diabetes, hypertension and dyslipidemia was ~15%-40% higher in patients with MACS. No pooled estimate was provided for mortality, however, in all 6 studies reporting on mortality, the RR was numerically increased. Quality of life was not reported as significantly different between patients with MACS and nonfunctioning adrenal incidentalomas.⁸ A small recent study analyzed an association of MACS and infections and described an increased susceptibility to infections in this patient cohort.¹⁴³

4.2.2. Surgery vs conservative management in patients with MACS (Question 2b)

Eleven studies were included in the systematic review⁶⁹ in which surgery was compared to a conservative approach: 2

randomized controlled trials (RCTs)^{144,145} and 9 observational cohort studies (Tables S10 and S11; Figure S2).^{140,146-153} The conservative treatments for the group of patients ranged from pharmacotherapeutic interventions for comorbidities to watchful waiting only. The quality of evidence from these cohort studies is low to very low, mainly due to confounding and the lack of a standardized protocol. The 2 RCTs were unblinded.

In summary, none of the included studies reported on the risk of major cardiovascular events or mortality. Improvement in glycemic control in the surgically treated patients was reported in both the RCTs as well as in 7 cohort studies. Similar improvements were shown for blood pressure control and dyslipidemia. In the largest RCT to date,¹⁴⁵ improvement in blood pressure control was shown in 68% of surgically treated patients, and in only 13.4% in the conservative arm. For improvement in glycemic control these numbers were 28% and 3.3%, respectively.

4.3 Surgical approach: open vs minimally invasive adrenalectomy in localized adrenocortical carcinoma (Question 3)

Since incomplete resection is the main risk for future adverse outcomes in patients with adrenocortical carcinoma, we focused our efforts with regards to surgical management of patient's presenting with adrenal incidentaloma undergoing adrenal surgery for suspected adrenocortical carcinoma

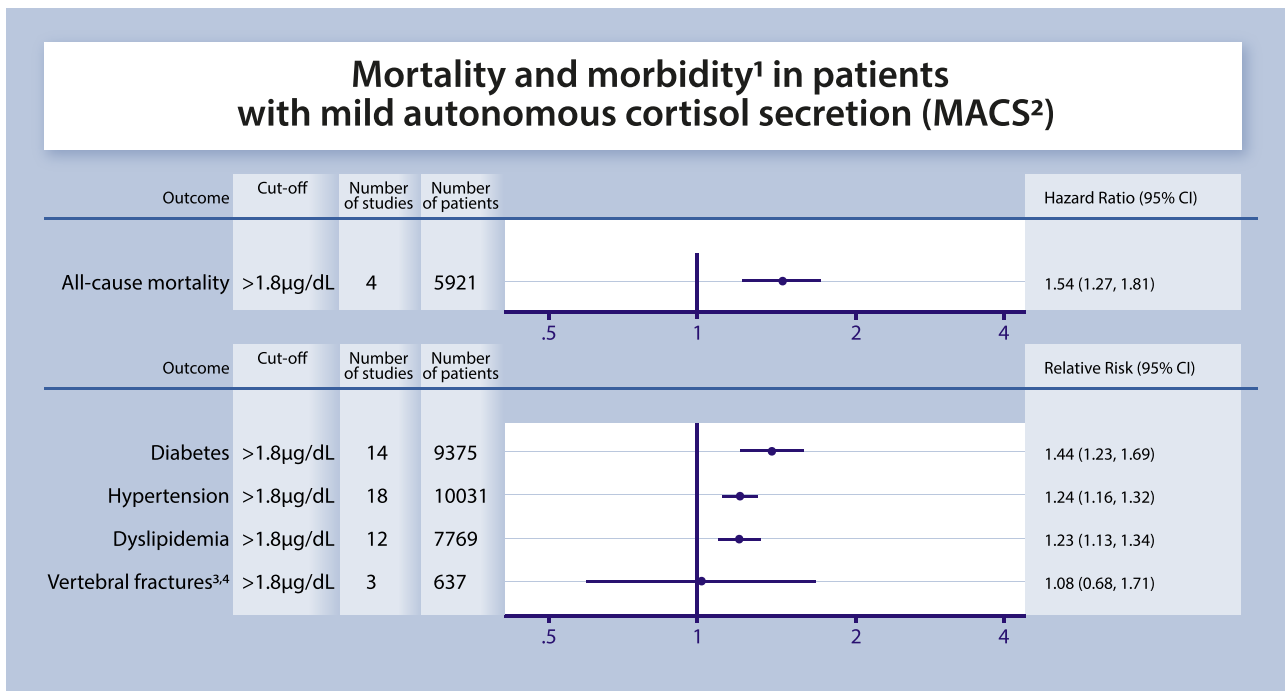


Figure 3. Morbidity in patients with mild autonomous cortisol secretion (MACS). ¹This is a summary figure of our systematic review. ⁶⁹ ²MACS was defined by a serum cortisol after 1 mg dexamethasone >1.8 µg/dL and the results were compared to patients with nonfunctioning incidentaloma. ³For vertebral fractures an association was found in few studies when a cutoff of 3 µg/dL is used. ⁴Including microfractures.

(Tables S12 and S13). Fourteen cohort studies on the surgical treatment of patients with nonmetastatic adrenocortical carcinoma were included.¹⁵⁴⁻¹⁶⁷ Four studies reported on the patients in whom complete resection of the tumor was achieved.^{156,158,162,166}

The quality of evidence from these observational studies is very low, mainly because patient groups were not comparable at baseline with regard to important prognostic characteristics, such as tumor stage or size. Tumor stage was, on average, lower in patients with minimally invasive surgery as compared to open surgery. In few studies,^{154,161,166} treatment effects were adjusted for differences in tumor stage or other confounders. Mostly, however, only uncorrected estimates of recurrence-free and overall survival were reported. Moreover, most studies had imprecise effect estimates.

Outcome measures

Perioperative mortality and morbidity. One study reported on perioperative mortality.¹⁵⁴ In this study, none of the 152 patients died perioperatively. Four studies reported on intraoperative or postoperative complications.^{157,158,161,167} Major postoperative complications (Clavien-classification score 3-5) occurred more often in open surgeries compared to minimally invasive surgeries (RR 1.7, 95% CI 0.5-6.2), but these estimates are imprecise.

Completeness of resection. In 8 studies the completeness of resection was reported.^{154,155,157,159,161,163,164,166} The pooled estimate of 6 studies (following the exclusion of studies with overlapping study cohorts) indicated no clear difference in the occurrence of complete resection between laparoscopic and open surgical approaches (RR 0.94 [95% CI 0.86-1.03]; Figure S3).^{154,155,157,159,161,164} The results of

these studies were inconsistent, and residual confounding is likely present, leading to much uncertainty regarding this conclusion.

Recurrence-free and overall survival. Eleven studies reported on recurrence after surgery but differed in the presentation of these data. These studies also provided data on overall or disease-specific survival.^{154-158,160-163,165,167} There is no compelling evidence that one of the approaches (minimally invasive or open adrenalectomy) is superior with regard to time to recurrence and/or survival in patients with adrenocortical carcinoma, provided that rupture of tumor capsule is excluded. However, the studies have relevant limitations, inconsistencies and imprecision precluding reliance on this conclusion.

Pain/patient satisfaction. None of the studies reported on pain or patient satisfaction.

Quality of life. None of the studies reported on mental health or quality of life.

4.4 Natural course of apparently benign adrenal incidentaloma (risk of malignancy or development of hormone excess) (Question 4)

Quantifying the risk of development of malignancy and overt hormone excess in a patient diagnosed with an apparently benign and nonfunctioning adrenal incidentaloma will dictate the intensity of follow up needed (Tables S14 and S15; Figure S4). We performed a systematic review of cohort studies assessing the emergence of features of malignancy or hormone excess during follow-up of adrenal incidentalomas initially classified as being nonfunctioning and benign.

In the 2016 version of this guideline, a combination of 14 studies included in a systematic review,¹⁶⁸ and 10 additional cohort studies were assessed.^{27,132-134,146,169-177} Now, 18 additional cohort studies were included, resulting in a total of 1 systematic review and 28 cohort studies.^{40,44,118,136,138,139,177-187}

The quality of evidence from these studies was judged moderate or low. Selection criteria were often not reported, the duration of follow-up was heterogeneous across studies (medians ranging from 19 months to 7 years) the completeness of follow-up was difficult to assess, and multiple studies had high loss to follow-up. Information on the protocol of biochemical or radiological reevaluation was not always provided or standardized. In addition, criteria for hormonal excess were heterogeneous across studies.

Outcome measures

Malignancy. In total, 10 studies (1 systematic review and 9 cohort studies) reported on the development of adrenal malignancy during follow-up.^{132,168,169,172,173,176,180-182,188} The estimated pooled risk for developing malignancy extracted from the systematic review was 0.2% (95% CI 0.0-0.4).¹⁶⁸ Notably, in 2 cohort studies included in the systematic review, 2 cases of malignancy were found: adrenal non-Hodgkin lymphoma and renal cancer metastasis.^{28,189} However, it is unclear whether these patients had features of benign incidentaloma at the time of initial imaging. In the 9 cohort studies included, no case of malignancy or malignant transformation was reported in 751 patients (follow-up range 1.6-5.8 years).^{132,169,172,173,176,180-182,188}

Development of clinically overt hormone excess.

Twenty-two cohort studies reported on results of consecutive dexamethasone tests.^{44,118,131,136,138,139,169,178,179,182-185,190} In the individual studies, the proportion of patients developing MACS varied from 0.0% to 31.4%, the latter clearly being an outlier. As shown in [Figure S4](#), the pooled proportions for development of MACS were 5.4% (95% CI 3.1%-8.1%).

The risk of developing overt Cushing's syndrome in patients without clinical signs of Cushing's syndrome at the time of initial assessment was reported by 9 studies (1 systematic review and 8 cohort studies).^{40,44,168,178,183,186,190} In total, the development of overt Cushing's syndrome in the individual studies ranged from 0.0% (reported in 7 cohort studies) to 0.65% (reported in 1 study,¹⁹⁰ which is similar to the risk reported in the previous systematic review of developing clinically overt Cushing's syndrome (with a pooled estimate of 0.3%).¹⁶⁸

The development of hyperaldosteronism during follow-up was reported by 10 studies.^{44,118,170,172,176,183,188,190,191} The risk of developing an aldosterone-producing adenoma in these studies ranged from 0.0%-1.64%, with solely 2 studies reporting one single case each.^{118,188}

The development of a pheochromocytoma during follow-up was reported by 13 studies (1 systematic review, 12 cohort studies).^{44,118,132,168-170,172,176,183,185,188,190} As reported by the individual studies, the risk of developing a secretory pheochromocytoma ranged from 0.0% (reported by 9 studies) to 2.1% (with 3 studies reporting cases,^{118,169,176} while the pooled risk of developing a pheochromocytoma was 0.2% based on the systematic review.¹⁶⁸ Unfortunately, it is not

clear in these studies if the baseline imaging and biochemical assessment was complete and adequate.

5. Recommendations, rationale for the recommendations

5.1. General remarks

The main part of this guideline addresses the management of patients who fulfill the definition of adrenal incidentaloma (Section 2.1). In addition, we discuss specific situations separately: bilateral adrenal masses (Section 5.6.1), patients who are young or elderly and frail (Section 5.6.2), and adrenal masses detected during evaluation for extra-adrenal malignancy (Section 5.6.3).

- R.1.1 We recommend that patients with adrenal incidentalomas are discussed in a multidisciplinary expert team meeting, if at least one of the following criteria is met:
 - Imaging is not consistent with a benign lesion (see Section 5.2).
 - There is evidence of hormone excess (including MACS in patients with clinically relevant comorbidities potentially attributable to cortisol) (see Section 5.3).
 - Adrenal surgery is considered (see Section 5.4).
 - Evidence of significant tumor growth during follow-up imaging (see Section 5.5).

The core multidisciplinary team should consist of an endocrinologist, a radiologist, and a surgeon, all with significant experience in the management of adrenal tumors.

Reasoning

We believe that the ideal would be for all patients with adrenal incidentalomas to be managed by an expert multidisciplinary team. However, in many health care settings this is an unrealistic scenario, considering the high number of incidentally discovered masses. Although there is still no compelling evidence available, there is some evidence that multidisciplinary care improves outcomes in patients with adrenal tumors.¹⁹²⁻¹⁹⁵ Thus, we aimed at identifying subgroups of patients who would be most likely to benefit from multidisciplinary team discussion and that these discussions occur quickly for patients that meet the above criteria. For this purpose, the center should establish standard operating procedures for the diagnostic and therapeutic work-up, because these standards will help to offer improved and standardized care to all patients. Our suggested pathway is summarized in [Figure 4](#). The above-mentioned multidisciplinary team should ideally include or at least have access to an endocrine pathologist, an oncologist, and an anesthetist, all experienced in adrenal tumors. Although it is beyond the scope of this guideline, the use of a standardized pathology report is highly recommended.¹⁹¹

5.2. Assessment of the risk of malignancy

- R.2.1 We recommend aiming to establish with the highest possible certainty if an adrenal mass is benign or malignant at the time of initial detection.

Reasoning

It is critical to know if an adrenal mass is malignant or benign as clinical management is dependent on establishing this fact, regardless of whether the mass is functioning or not.

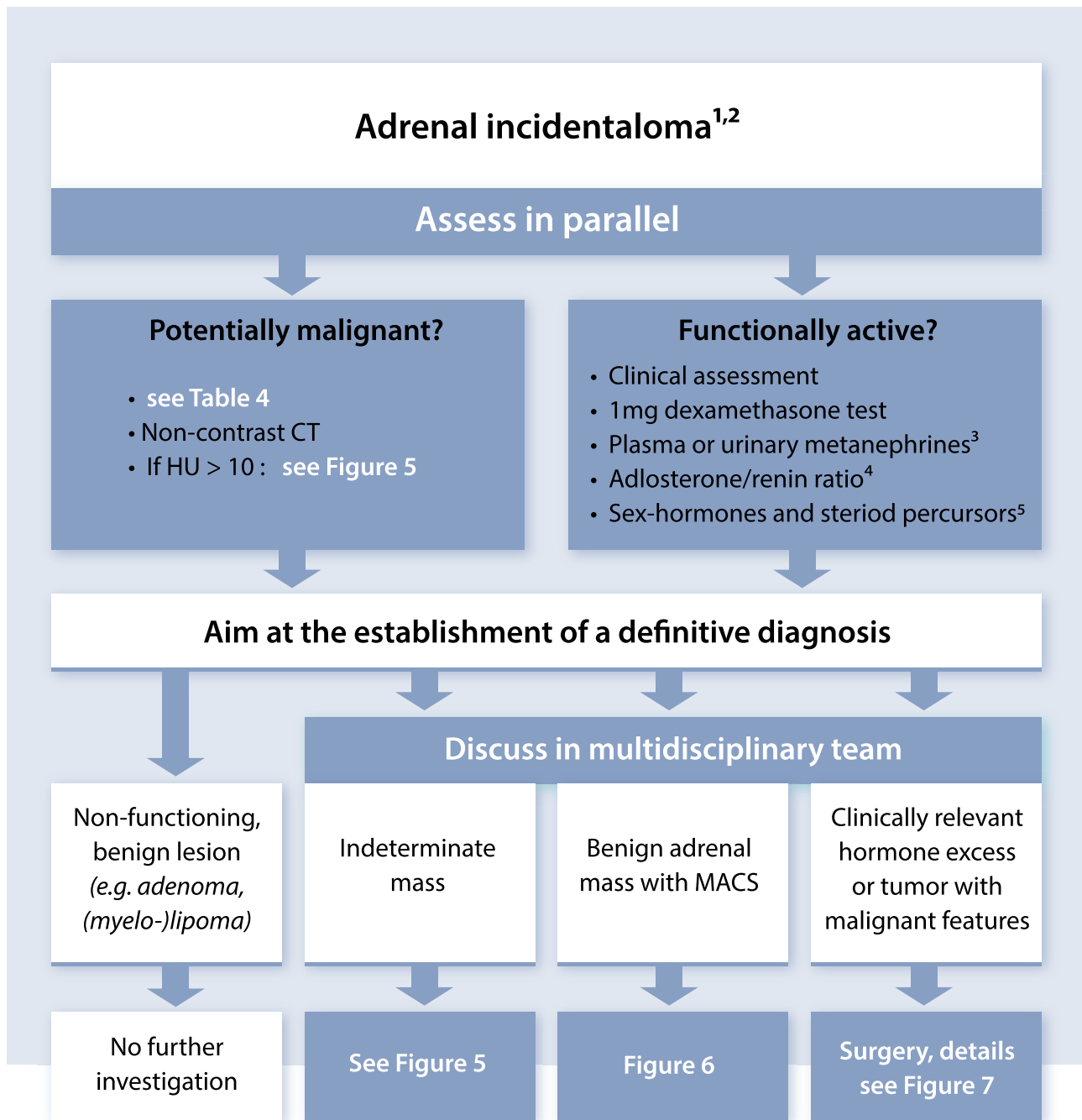


Figure 4. Flow-chart on the management of patients with adrenal incidentalomas (overview). ¹For patients with history of extra-adrenal malignancy, see special Section 5.6.3. ²In a small subset of patients (eg, masses > 4 cm with malignant imaging features, age <40 years, pregnancy, patients with severe adrenal hormone excess) an urgent assessment is needed. ³Only necessary in adrenal tumors with Hounsfield unit (HU) > 10 in unenhanced CT. ⁴Only in patients with concomitant hypertension and/or hypokalemia. ⁵Only in patients with clinical, biochemical, or imaging features suggestive of adrenocortical carcinoma.

Malignant lesions may need urgent surgical intervention and other therapies, and delay may cause harm. Therefore, it is crucial that all images of patients with adrenal incidentaloma are reviewed by an experienced radiologist; also focusing on the contralateral adrenal, which is not rarely also hyperplastic or nodular.

- R.2.2 We recommend that all adrenal incidentalomas undergo an imaging procedure to determine if the mass is homogeneous and lipid-rich and therefore benign (⊕⊕⊕⊕). For this purpose, we recommend the use of

noncontrast CT as the first imaging modality if not yet performed (⊕⊕⊕⊕).

- R.2.3 We recommend that if the noncontrast CT is consistent with a benign adrenal mass (homogenous appearance and HUs ≤ 10) no further imaging is required (⊕⊕⊕⊕) (Figure 5).

Reasoning

In patients with no known extra-adrenal malignancy, adrenal incidentalomas are likely to be benign. The noncontrast

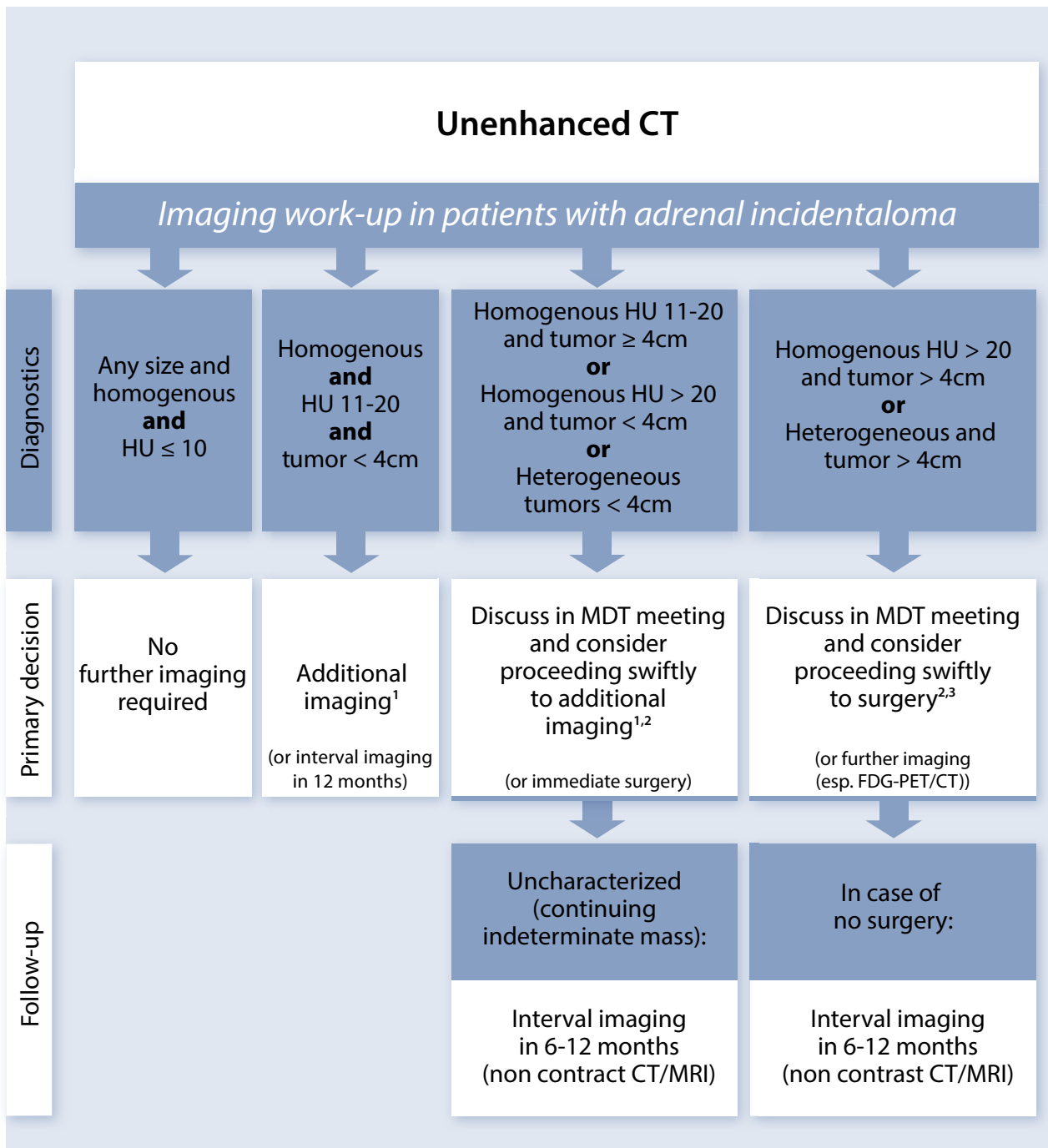


Figure 5. Imaging work-up in patients with adrenal incidentaloma. This figure is designed to provide overall general guidance as it is not possible to account for every clinical eventuality in a single figure; MDT discussion is especially important in any cases of doubt. ¹Additional imaging can vary according to the center expertise and availability including FDG-PET/CT, adrenal MRI with CSI, or washout CT. ²In case of bilateral lesions with similar imaging feature, biopsy could be considered (see also R.6.3.5). ³After complete tumor staging including CT thorax, abdomen and pelvis.

CT HU value is reflective of tissue density. Benign lesions including lipid-rich adenoma, myelolipoma, and fluid-filled homogenous cysts have low CT density ≤ 10 HU. Based on our systematic reviews and meta-analyses in 2016⁷⁶ and in 2022 (see Section 4.1), in 3723 patients presenting without known malignancy a noncontrast CT HU of ≤ 10 was only found in benign disease.^{1,8,44,50,71-74}

Thus, with more supportive evidence since the previous guidelines, the panel felt confident about the negative predictive value of noncontrast CT to recommend that additional

imaging was not necessary when unequivocal benign characteristics were found, especially as additional imaging (Table 4) may risk false positive results and subsequent psychological and financial burden for patients and the health system. Due to better evidence derived from observations in 1197 patients with tumors ≥ 4 cm,^{8,10} we have removed the size cut-off of 4 cm that we introduced, arbitrarily, in 2016.

Similar to CT, the results of MRI with chemical shift imaging are based on the lipid content of masses.^{196,197} Unlike CT (and FDG-PET), MRI has the advantage of avoiding

Table 4. Imaging criteria to discriminate benign from malignant adrenal masses.^a

Method	Criteria favoring a benign mass	Strength of evidence ^b
Noncontrast CT	≤ 10 HU ^c	⊕⊕⊕⊕
FDG-PET/CT	Absence of FDG uptake or uptake less than the liver ^d	⊕○○○
MRI—chemical shift	Loss of signal intensity on out-phase imaging consistent with lipid-rich adenoma	⊕○○○
CT with delayed contrast media washout ^e	Relative washout > 58% ^f	⊕○○○

^aThese criteria apply only for masses with homogenous appearance, or masses that have other clear characteristics consistent with benign disease, eg, myelolipoma. A homogeneous mass is defined as a lesion with uniform density or signal intensity throughout. The measurements/region of interest (ROI) should include at least 75% of a lesion without contamination by tissues outside the adrenal lesion. Nonhomogeneous lesions should not be subjected to MRI or washout CT for further characterization.

^bThe strength of recommendation based on our systematic review on this topic (Section 4.1.1) and our personal experience.

^cThe majority of adrenal masses with HU 11–20 are also benign, especially in patients without history of extra-adrenal malignancy (see Section 4.1.1 and Reasoning R.2.4 for details).

^dCertain metastasis (eg, from kidney cancer or low grade lymphoma) may be FDG negative.

^eThere is no clear evidence about the best time interval. However, experienced adrenal radiologists prefer 15 min over 10 min.

^fThis cutoff based on a single study with only 253 adrenal tumors⁷² and has to be judged with caution and several older studies suggest a cutoff of 40%. Abbreviation: HU, Hounsfield unit.

ionizing radiation and its attendant risks to the patient. However, the quantitative assessment of loss in signal intensity is not well standardized between different studies and, therefore, the evidence base for the performance of MRI in the diagnosis of malignancy is insufficient to make strong recommendations (see Section 4.1). Moreover, the interpretation of the images might be more dependent on the experience of the radiologist than that for quantitative CT assessment. In addition, the meta-analysis was not able to determine the diagnostic value of MRI, especially compared to CT, due to the low number and quality of eligible studies. In the last 6 years, no study on MRI fulfilling our selection criteria has been published. One very recent study was published at the beginning of 2023 and suggests utility of MRI even in adrenal lesions with heterogeneous microscopic fat ($n = 283$).¹⁹⁸ However, MRI with chemical shift should still be first choice only where a CT is less desirable (eg, pregnancy, children). Nevertheless, if an MRI with chemical shift is already performed and the results are unambiguous, a multidisciplinary expert team might judge this as sufficient for an individual patient.

- R.2.4 If CT demonstrates a homogeneous adrenal mass with unenhanced HU between 11 and 20 and a tumor size < 4 cm, and the results of the hormonal work-up do not indicate significant hormone excess, we suggest an immediate additional imaging (Table 4) to avoid any follow-up imaging (⊕○○○) (Figure 5). Alternatively, interval imaging in 12 months by noncontrast CT (or MRI) could be performed.
- R.2.5 If the adrenal mass is ≥ 4 cm and heterogeneous or has unenhanced HU > 20, there is a relevant risk that this lesion is malignant. Therefore, we suggest discussing such

cases in a multidisciplinary team meeting. In most cases, immediate surgery will be the management of choice, but in some patients, additional imaging might be an option (⊕○○○). Prior to surgery, we suggest completely staging the patient (including at least thoracic CT and/or FDG-PET/CT (⊕○○○)). If surgery is not performed, follow up imaging in 6–12 months is recommended (⊕○○○).

- R.2.6 In adrenal masses that do not fall in one of the categories above (eg, tumor size ≥ 4 cm with unenhanced HU 11–20; or tumor size < 4 cm with unenhanced HU > 20; or tumor size < 4 cm with heterogeneous appearance), we suggest an individualized approach with discussion in a multidisciplinary team meeting (⊕○○○). The likelihood of a malignant tumor is still low. Therefore, in most cases, immediate additional imaging according to the center expertise and availability is the preferred option. If the tumor is still judged as indeterminate mass and surgery is not performed, we recommend interval imaging in 6–12 months (noncontrast CT/MRI) (⊕○○○).

Reasoning

The panel decided to divide the group of tumors with HU > 10 into 3 groups (Figure 5). For this purpose, we used based on recent studies^{8,10,70,75} the appearance of the mass, tumor size, and HU as cutoffs. As described in section 4.1, there is increasing evidence that, especially in patients without history of extra-adrenal malignancy, > 90% of the homogeneous adrenal tumors with unenhanced HU between 11 and 20 are benign.^{1,8,44,72,73} However, there are some metastases and very few adrenocortical carcinoma with HU in this range.^{8,72} Thus, in adrenal masses < 4 cm and HU between 11 and 20 (without hormonal activity), the first choice is one additional imaging method (depending on the local experience and preference FDG-PET/CT, MRI with chemical shift or washout-CT). If these imaging results are suggestive of a benign lesion, no further imaging is required. Our second choice would be a follow-up imaging to monitoring just the size of the lesion by noncontrast CT (or MRI). For this purpose imaging focusing just on the adrenal seems reasonable. Due to the low likelihood of malignancy, a 12-month interval would seem to be reasonable for the majority of patients.

In contrast, if the tumor size is ≥ 4 cm and has unenhanced HU > 20 or a heterogeneous appearance, the risk of malignancy is clearly increased. In tumors that fulfill both categories, the likelihood of a malignant lesion even in a “true” incidentaloma cohort could be as high as 50%.⁸ Therefore, a multidisciplinary team meeting should discuss this case in detail. In most cases, the option of surgery should be offered to the patient. Prior to surgery, a complete tumor staging should be performed, because the detection of other potentially malignant lesions will most likely modify clinical management. In this context, a thoracic CT is essential, because small lung metastases are relatively frequent in adrenocortical carcinoma. Therefore, our recommendation to use FDG-PET/CT alone in this case applies only if CT component of the study is of routine diagnostic quality.

However, there are some tumors that do not fall the categories above. Based on our own experience and the available literature,^{8,10,70,75} we judge the risk of malignancy in this subgroup still rather small, but higher as in tumors < 4 cm and HU 10–20. Therefore, instead of immediate surgery, additional imaging seemed most appropriate. Although, the evidence of targeted evaluation for “second or third-line”

imaging in patients with indeterminate adrenal mass is still limited (see Section 4.1), most panelists judged the value of FDG-PET/CT higher than that of MRI or CT with delayed washout. FDG-PET/CT has the advantage that the risk of false negative results (namely missing a malignant adrenal tumor) is quite low,^{49-52,83-85,199-202} but it is clearly not zero²⁰³ (Table 4). This procedure is, however, more expensive, not always easily available, and has the disadvantage that several benign adrenal tumors (eg, functional adenomas) may be FDG-positive lesions.^{204,205} The advantages and limitations of MRI with chemical shift are already discussed at R.2.3. Furthermore, there might be a publication bias, because adrenal MRI with chemical shift is judged as quite established and new studies on this topic might be seen as less attractive. Therefore, the multidisciplinary team should decide based on local expertise and availability which additional method is used. For washout CT, 1 recent study provided some evidence that a relative percentage washout of >58% might be a more appropriate cutoff.⁷² However, this cutoff requires to be confirmed by other studies. If the additional imaging is suggestive of a malignant lesion, then surgery is advised. If the mass is still uncharacterized, but no surgery is performed, a follow-up imaging in 6-12 months is advised.

A promising alternative, where available, with high specificity for adrenocortical carcinoma is urine steroid metabolomics, combining urine steroid profiling by tandem mass spectrometry with machine learning-based steroid data analysis. In a prospective study with more than 2000 patients with adrenal incidentaloma, this approach had positive predictive value of 76.4% and a negative predictive value of 99.7%.⁸

In the case of second-line imaging or urine steroid metabolomics suggesting benign disease, or for any other reason surgery was not performed, follow-up imaging in 6-12 months depending on the individually perceived risk of malignancy is the preferred strategy (except for tumors <4 cm and HU 11-20 that do not need such interval imaging). Since there are very few adrenocortical carcinomas that grow very slowly, few panelists even preferred imaging both after 6 and 12 months.

There are no published or commonly agreed size or volume cutoffs that may be used that indicate growth suggestive of malignancy; the expert panel agreed in line with RECIST 1.1 criteria, an increase of >20% of the largest tumor diameter together with at least 5 mm increase in this diameter should be considered as suspicious.

However, if there is no change in size, no further imaging is needed.

- R.2.7 We recommend against the use of an adrenal biopsy in the diagnostic work-up of patients with adrenal masses unless there is a history of extra-adrenal malignancy (see R.6.3.5).

Reasoning

Adrenal biopsy has a limited role in evaluation of adrenal masses—mainly in diagnosis of extra-adrenal malignancy, lymphoma, sarcoma, infiltrative or infectious process.^{11,206} Even in such situations, adrenal biopsy should be performed only after exclusion of a pheochromocytoma and by physicians experienced in this procedure and when it affects management decisions.^{86,91,207} We particularly recommend against an adrenal biopsy if an adrenal mass is likely to be

an adrenocortical carcinoma, because a biopsy of such a tumor runs the risk of tumor dissemination, precluding an R0 resection. It has been reported to lead to worse overall survival in patients with stages 1 and 2 adrenocortical carcinoma.²⁰⁸ The only exceptions might be if a formal confirmation of the diagnosis is needed in an inoperable tumor to inform oncological management or as part of a clinical trial.

- R.2.8 We suggest measurement of sex steroids and precursors of steroidogenesis (ideally using multiteroid profiling by tandem mass spectrometry) in patients in whom by imaging or clinical features an adrenocortical carcinoma is suspected (⊕⊕○○).

Reasoning

Adrenocortical carcinoma is associated in more than half of cases with elevated sex hormones and/or steroid precursors.²⁰⁹⁻²¹² The panel does not recommend measurement of these hormones in patients with adrenal incidentalomas on a routine basis, but in cases with indeterminate adrenal mass by imaging or clinical signs for androgen or estrogen excess (eg, rapid virilization in women or rapidly developing gynecomastia in men), significantly increased sex hormones or precursors might clearly point toward adrenocortical carcinoma. Thus, measurement of serum DHEA-S, androstenedione, 17-hydroxyprogesterone, 11-deoxycortisol, as well as testosterone in women and estradiol in men and postmenopausal women can give clear indication of the adrenocortical nature of the adrenal mass. However, the panel acknowledges that the published evidence for this suggestion is very low.^{95,210} Analysis of a comprehensive serum or urinary steroid profiles measured by GC-MS or LC-MS was found useful to discriminate benign from malignant adrenocortical tumors.^{95-99,213} By combining the results of a machine learning algorithm processing urine steroid multi-profiling data with CT features (tumor size and HU on unenhanced CT), a prospective study on this topic with more than 2000 patients demonstrated that it is possible to reduce significantly the number of surgeries of indeterminate tumors wrongly suspected to be adrenocortical carcinoma.⁸ Therefore, the evidence is strongest for this method. However, urine steroid metabolomics is not yet widely available and is only validated and standardized in very few laboratories. Furthermore, it is not able to identify nonadrenocortical malignant adrenal masses.

5.3. Assessment for hormone excess

- R.3.1 We recommend that every patient with an adrenal incidentaloma should undergo careful assessment including clinical examination for symptoms and signs of adrenal hormone excess.

Reasoning

All patients should undergo a careful evaluation with detailed history and physical examination to detect clues of overt hormone excess, as certain features are nonspecific and may be missed. For the clinical assessment and subsequent diagnostic procedures for Cushing's syndrome, primary aldosteronism, and pheochromocytoma, we refer to other guidelines.⁶¹⁻⁶³

Rapid onset and progression of hirsutism or virilization is a clinical indicator for an androgen-producing tumor and

should be addressed by measuring serum testosterone and androgen precursors DHEA(S) and androstenedione, whereas recent onset of gynecomastia should trigger measurement of serum 17-beta-estradiol^{211,212,214,215} (see also R.2.8).

- R.3.2 We recommend that patients with adrenal incidentalomas undergo a 1-mg overnight dexamethasone suppression test to exclude autonomous cortisol secretion (⊕⊕⊕⊕). In frail patients with limited life expectancy, this test may not be warranted.
- R.3.3 We recommend interpretation of the results of the 1-mg overnight dexamethasone test as a continuous rather than categorical (yes/no) variable (⊕○○○). However, we recommend using serum cortisol levels post dexamethasone ≤ 50 nmol/L (≤ 1.8 $\mu\text{g/dL}$) as a diagnostic criterion for the exclusion of autonomous cortisol secretion (⊕⊕○○).
- R.3.4 We recommend that in patients without signs and symptoms of overt Cushing's syndrome a postdexamethasone serum cortisol concentration above 50 nmol/L (>1.8 $\mu\text{g/dL}$) should be considered as MACS without any further stratification based on the degree of cortisol nonsuppressibility (⊕⊕○○). In these patients, we recommend that ACTH-independency should be confirmed. Conditions that alter the results of the 1 mg DST should be considered for the interpretation of the results of the test. A repeat DST to confirm cortisol secretory autonomy is recommended. Additional biochemical tests to assess the degree of cortisol secretion might be useful. However, for clinical management, the presence of comorbidities potentially attributable to cortisol excess (Table 5), age, and the general condition of the patient are major factors for clinical decision-making (Figure 6).

Reasoning

A variety of diagnostic algorithms have been used to exclude cortisol excess or to define the formerly so-called "subclinical hypercortisolism," but in the literature there are no head-to-head comparisons between tests to assess their diagnostic performance (see Section 4.2.1); also formal comparisons between algorithms and relevant clinical outcomes are lacking. In the 2016 ESE-ENSAT guidelines, however, the panel recommended the use of the 1-mg overnight dexamethasone test based on pathophysiological reasoning, simplicity, and the fact that the test was incorporated in the diagnostic algorithms of most studies. Following the release of the ESE-ENSAT guidelines, studies have increasingly relied on the results of a 1-mg DST to categorize patients^{12,39,40,113,114,116,117,119,120,123,125,137,138,141}

The panel believes that cortisol autonomy reflects a biological continuum with no clear separation between nonfunctioning adenomas and functioning adenomas associated with some degree of cortisol excess. However, considering current evidence, a value of ≤ 50 nmol/L (≤ 1.8 $\mu\text{g/dL}$) may be regarded as physiologic, excluding cortisol excess. Thus, a cutoff value of 50 nmol/L for post-DST cortisol has been consistently used to differentiate cortisol autonomy from normal secretion. In some studies, patients with nonsuppressed cortisol after 1 mg dexamethasone have been further stratified in 2 categories following the previous recommendations of the ESE-ENSAT guidelines, that is, patients with post-DST cortisol levels between 50 and 138 nmol/L (1.9-4.9 $\mu\text{g/dL}$) and

Table 5. Metabolic comorbidities potentially attributable to cortisol (see⁶⁹ for details).^a

	Prevalence (%) in patients with ACS ^b	Prevalence (%) in patients with nonfunctioning incidentalomas ^b	Relative risk ^b
Type 2 diabetes mellitus	13-54	14-39	0.94-3.14
Hypertension	46-88	30-68	0.69-1.69
Dyslipidemia	26-67	25-49	0.71-1.92

^aMACS was defined by a serum cortisol after 1 mg dexamethasone > 50 nmol/L (> 1.8 $\mu\text{g/dL}$).

^bReported ranges.

Abbreviation: MACS, mild autonomous cortisol secretion.

patients with levels of 138 nmol/L, or higher.^{12,39,40,141} Any cutoff value of post-DST cortisol has an overall poor accuracy to predict prevalent comorbidities;^{69,110} however, different studies showed a relationship between progressively increased post-DST cortisol levels and higher rate of comorbidities although the pattern is not linear.^{12,39,40,123} One large cohort study found that mortality was significantly increased only when post-DST cortisol values were ≥ 83 nmol/L (3 $\mu\text{g/dL}$),³⁹ a finding that warrants replication in future studies. Finally, the panel judged that there is convincing evidence that the cutoff at >50 nmol/L (>1.8 $\mu\text{g/dL}$) differentiates patients at increased risk of comorbidities and death, while there is no clear evidence to further differentiate patients on the degree of cortisol nonsuppressibility. Therefore, the panel argues that the previous stratification between "possible autonomous cortisol secretion," when serum cortisol post dexamethasone is between 51 and 138 nmol/L, and "autonomous cortisol secretion," when serum cortisol is higher than 138 nmol/L, should be abandoned and finally suggested the term "MACS." The patients who suppress cortisol below 50 nmol/L do not need any further evaluation or follow-up by an endocrinologist. In patients with MACS, a careful second clinical evaluation might be necessary to search for signs of overt Cushing's that may have been overlooked at first examination, and to confirm ACTH independency by demonstrating suppressed or at least low-normal morning plasma ACTH (Figure 6). Some panelists felt that the measurement of serum DHEA-S or age- and sex-adjusted DHEAS ratios is helpful to identify patients with relevant MACS, especially in patients at risk of false positive of the 1 mg DST, because DHEA-S is decreased when the hypothalamus-pituitary-adrenal axis is chronically suppressed.²¹⁶⁻²¹⁸ However, age-adjusted DHEA-S reference values are not well established. Recently, a new approach to diagnose ACTH independency was suggested by measuring ACTH after a 1 mg DST,²¹⁹ but these results have to be confirmed.

Further, the assessment of the presence of comorbidities potentially attributable to cortisol (Table 5) becomes of utmost importance to guide management. However, we are well aware that the likelihood of comorbidities increases with age. Furthermore, with increasing age cortisol after 1 mg DST is also increasing,¹² and there is evidence that in patients > 65 years the clinical relevance of MACS is decreasing.⁴⁰ Thus, this aspect has to be considered individually. In particular, in frail patients the documentation of MACS is very

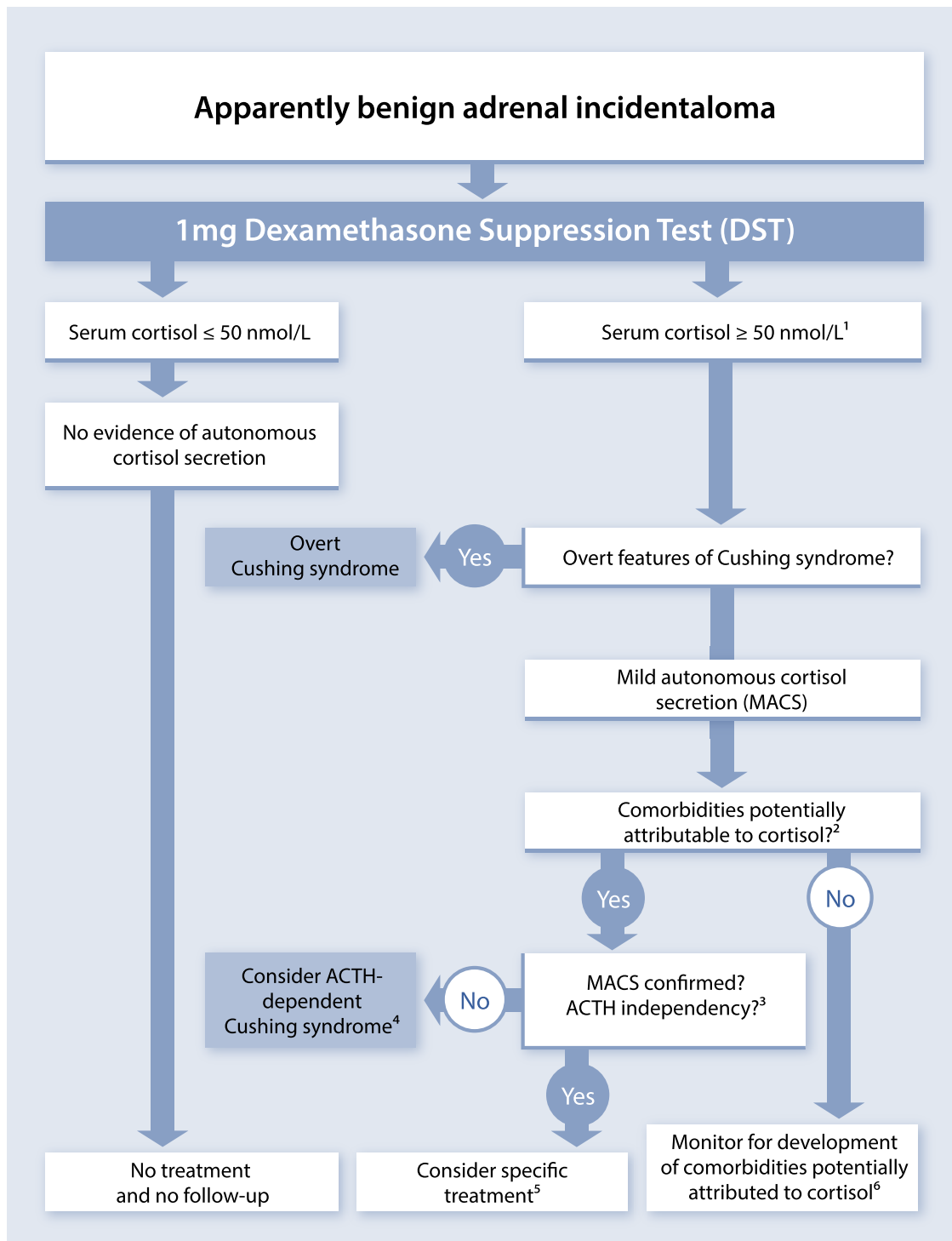


Figure 6. Assessment and management of mild autonomous cortisol secretion (MACS) in patients with adrenal incidentalomas. ¹Factors leading to false positive results have to be considered (see Table S16). Some panelists measure plasma ACTH already at this stage to prove ACTH-independency. ²The term comorbidities attributable to cortisol are defined broadly and includes diabetes mellitus, hypertension, dyslipidemia, or osteoporosis. ³Defined by low/suppressed morning plasma ACTH (and/or low age-adjusted DHEAS). ⁴An appropriate clinical context for triggering screening of ACTH-dependent Cushing is the presence of even mild stigmata of cortisol excess and/or clinically relevant comorbidities. ⁵Surgery is usually only indicated if comorbidities fulfill one or more of the following features: progressive; difficult to treat; associated with inappropriate end organ damage for age; unusual for age or discrepant from family history; or multiple comorbidities. In addition, age, sex, general health, degree, and persistence of nonsuppressible cortisol after dexamethasone, and patient's preference should be taken into account. ⁶Annual clinical reassessment of comorbidities potentially attributable to cortisol is recommended. If adequate surveillance for comorbidities is available in the community, this does not require a specialized endocrine follow-up. If these comorbidities develop or worsen, referral to an endocrinologist is suggested to reassess the endocrine status and reconsider the potential benefit of intervention.

likely irrelevant and has no clinical consequences. Thus, the DST should be omitted in this patient group unless overt Cushing's syndrome is suspected.

Patients without detectable comorbidities should not undergo a specific treatment (ie, surgery) but require follow-up for the development of comorbidities potentially attributable to cortisol (see R.5.4), while a subset of patients with relevant comorbidities should be considered for specific treatment (see also R.3.8; Figure 6).

Some panel members (but not all) preferred additional biochemical tests to confirm cortisol secretory autonomy and assess the degree of cortisol secretion. However, we acknowledge that the use of several tests may be associated with an increased likelihood of at least one being a false positive result. As the cortisol after 1 mg dexamethasone might not correlate with the degree of cortisol secretion, some panelists perform the additional measurement of 24-hour urinary free cortisol and/or late-night salivary cortisol. However, depending on the assay, these results are within the normal range in most patients without overt Cushing's syndrome. Thus, pathological results might indeed point toward a more advanced phenotype. Similarly, few panelists use a higher dose of dexamethasone (eg, 3 mg, 2 × 2 mg, or 8 mg) following the concept that cortisol secretion in patients with MACS is independent of ACTH. However, the published literature is too limited and controversial to make a clear statement on these tests.^{108,124,220}

One major problem with this categorical definition between "healthy" and "potentially ill" (MACS) derives from less than ideal sensitivity and specificity of the DST to diagnose or exclude MACS. We are well aware that every laboratory should actually validate the given cutoff locally. However, this cumbersome procedure may be unrealistic for many centers, but all clinicians should be aware of this limitation and should base their clinical decision on management not only on this single parameter. Due to the fact that there will be false-positive results on dexamethasone testing, the test should be repeated in all patients with MACS in whom surgery is considered as a therapeutic option. Measurement of serum dexamethasone alongside serum cortisol in the 1-mg DST may help excluding false positive DST results due to poor absorption or increased dexamethasone metabolism.²²¹⁻²²⁴ However, this method is not yet widely available.

- R.3.5 We recommend against considering patients with MACS (per definition without specific clinical signs of Cushing's syndrome) as being at high risk for development of overt Cushing's syndrome (⊕⊕⊕○).

Reasoning

Studies reporting on follow-up of patients with adrenal incidentalomas have uniformly found a very low percentage (<1%) of patients with MACS progressing to overt Cushing's syndrome^{19,25-28,30-32,40,168,225} (see also Section 4.4).

- R.3.6 We recommend screening patients with adrenal incidentaloma and MACS for hypertension and type 2 diabetes mellitus (⊕⊕○○) and suggest offering appropriate treatment of these conditions.

Reasoning

There is an increasing body of evidence on an association between MACS and either hypertension

or hyperglycemia^{12,29,39,40,103,108,110,112-114,117,118,120,123,124,126,138,140,141,226-232} (see also section 4.2.1 and⁶⁹). The association with dyslipidemia is less solid, although biologically plausible.^{12,110,117,118,121,123} Therefore, the panel is clearly in favor of screening for these conditions, which are well known independent cardiovascular risk factors, and which may be driven by cortisol excess, and to treat them according to current guidelines. For this screening the following measures seems reasonable: blood pressure (ideally as ambulatory measurement), HbA1c, LDL and HDL cholesterol, triglycerides, and body weight. There is also evidence that MACS is associated with an increased risk of cardiovascular events and excess mortality.^{39,40,130,131,139,142}

- R.3.7 We suggest screening patients with adrenal incidentaloma and MACS for vertebral fractures (⊕○○○) and to consider appropriate treatment of these conditions (⊕○○○).

Reasoning

Some^{101-104,133,146,233} but not all studies^{109,119,137} found an increased incidence of asymptomatic vertebral fractures. However, accurate assessment of (micro-) fractures on X rays is not part of clinical practice everywhere. Therefore, at least overt fractures should be identified at the time of diagnosis. This can be done by asking patients about a history of non-traumatic fracture and, possibly, by reevaluating the available images (CT scan) or by plain X-ray.

Assessment of bone mineral density by dual-energy X-ray absorptiometry has been shown to be a suboptimal tool to diagnose glucocorticoid-induced osteoporosis since glucocorticoid excess has a greater impact on bone microarchitectural texture than on areal bone mineral density.^{234,235} Furthermore, conflicting results on bone mineral density in patients with MACS have been found. Few studies using noninvasive radiological evaluation of bone microarchitecture such as trabecular bone scan found qualitative bone deterioration in MACS.^{104,234,236} However, the number of these studies is small requiring further confirmation (see also section 6) and radiological evaluation of bone microarchitecture is not widely available. We therefore suggest to consider BMD especially in patients with MACS with clinical suspicion of osteoporosis or in the presence of associated risk factors for osteoporosis.

- R.3.8 We recommend discussing the option of surgery with the patient who has MACS in addition to relevant comorbidities and a unilateral adrenal mass (⊕○○○). Age, sex, general health, degree and persistence of non-suppressible cortisol after dexamethasone, severity of comorbidities and patient's preference should be taken into account (⊕○○○). In all cases, the proposal to perform surgery should be established within an expert multidisciplinary group.

Reasoning

Due to the limitations of current literature, especially the lack of high-quality randomized trials, the panel could not define the exact indications for surgery for patients with MACS. The panel appreciated that there is some evidence of improvement of hypertension and hyperglycemia with surgery, but this is largely based on low quality data.¹⁴⁶⁻

148,150-152 In addition, there are 2 small randomized trials that point in this direction.^{144,145} However, the evaluation and treatment of comorbidities in operated and nonoperated patients after randomization were not standardized, preventing an accurate assessment of the benefits of surgery. Furthermore, no data are available on more clinically relevant endpoints (eg, mortality or major cardiovascular events). Thus, the decision to undertake surgery should be individualized considering factors that are linked to outcome, such as patient's age, degree and persistence of cortisol autonomy on at least 2 separate evaluations, duration and evolution of comorbidities and their degree of control, and presence and extent of end organ damage. Because it is not possible to predict accurately the results of surgical intervention on the clinical phenotype of an individual patient, there was no complete agreement within the panel regarding the optimal management of these patients. Overall, the group agreed that there may be an indication for surgery in a patient with a unilateral adrenal mass, a post dexamethasone cortisol >50 nmol/L (>1.8 µg/dL) and the presence of at least one of the following features in the comorbidities potentially attributable to cortisol: (1) progressive; (2) difficult to treat; (3) associated with inappropriate end organ damage for age; (4) unusual for age or discrepant from family history; or (5) multiple comorbidities. Given the lack of specific evidence, the panel felt that the presence of (some of) these features may suggest that normalization of cortisol autonomy has a greater likelihood to benefit patients who are operated on. Interestingly, there are 2 recent, large studies that suggest that mortality of patients with MACS is mainly increased in the cohort below the age of 65 years^{40,237} and in one of these studies particularly women younger than 65 years were affected.⁴⁰ Thus, these patient group could potentially benefit most from a therapeutic intervention. However, data from intervention studies are not available yet.

However, there was consensus that when surgery is considered due to MACS, ACTH-independency has to be proven by a suppressed or low basal morning plasma ACTH. If not, other reasons for cortisol excess have to be considered. Moreover, the panel felt that cortisol nonsuppressibility should be confirmed by repeating a 1-mg DST prior surgery.

In theory, an alternative approach could be medical therapy. However, the evidence for such an approach is still too low to give any recommendation.

- R.3.9 We recommend excluding pheochromocytoma by measurement of plasma free metanephrines or urinary fractionated metanephrines in all patients with adrenal lesions with features not typical for a benign adenoma (eg, unenhanced HU > 10).

Reasoning

Recent studies have consistently shown that the possibility that an adrenal tumor with HU ≤ 10 in unenhanced CT be a pheochromocytoma is close to zero.^{7,238,239} Thus, it seems to be reasonable to avoid measuring metanephrines in patients with clear CT features of an adrenal adenoma. This holds probably also true, if an adrenal MRI with chemical shift clearly indicated an adenoma. However, here are no published data available. In patients with indeterminate imaging features, pheochromocytoma should be excluded even in the

absence of suggestive symptomatology,⁷ particularly if biopsy or removal of the tumor is planned. If no unenhanced CT is performed, it is advisable to measure plasma free metanephrines or urinary fractionated metanephrines.

- R.3.10 In patients with concomitant hypertension or unexplained hypokalemia, we recommend use of the aldosterone/renin ratio to evaluate primary aldosteronism.

Reasoning

For details we refer to the most recent guidelines of other societies and reviews (eg,^{63,240-244}).

5.4. Surgical treatment

- R.4.1 We recommend adrenalectomy as the standard of care for unilateral adrenal tumors with clinically significant hormone excess (Figure 7). In patients with MACS, surgery can be considered in patients with relevant comorbidities, taking into account individual factors (detailed in R.3.8).

Reasoning

As covered by several other guidelines, there is consensus that adrenal tumors leading to clinically significant hormone excess (eg, primary aldosteronism, Cushing's syndrome, or pheochromocytoma) should be surgically removed.^{36,62,63,241} In patients with MACS, surgery can be considered in patients with relevant co-morbidities, taking into account individual factors (detailed in R.3.8). The guideline group is convinced that for these tumors the same rules regarding the surgical approach should apply as for endocrine inactive tumors (see below). There are no substantiated reasons why the surgical approach for hormone-producing tumors should differ from that in endocrine inactive tumors (R.4.4-4.6).

- R.4.2 We recommend against performing surgery in patients with an asymptomatic, nonfunctioning unilateral adrenal mass and obvious benign features on imaging studies (⊕⊕○○).

Reasoning

Most adrenal incidentalomas are nonfunctioning benign lesions (eg, adenomas, myelolipomas) that do not cause harm. Therefore, there is broad consensus that the majority of these adrenal masses do not require surgery. The guideline group defined 2 criteria that need to be fulfilled to allow characterization of a unilateral adrenal lesion as not harmful: (1) imaging criteria indicating a benign lesion (see Section 5.2, Table 4) and (2) no relevant endocrine activity (see Section 5.3).

Regardless of size, when imaging characteristics suggest a benign nature of the mass, adrenalectomy is routinely not indicated. However, following careful MDT discussion, a more individualized approach may be considered including considering surgery for alleviation of symptoms of mass effect (eg, large myelolipoma with progressively increasing size). Finally, we voted against a certain size cutoff that indicates that surgery has to be performed. However, we acknowledge that with a larger tumor size, patients and clinicians might

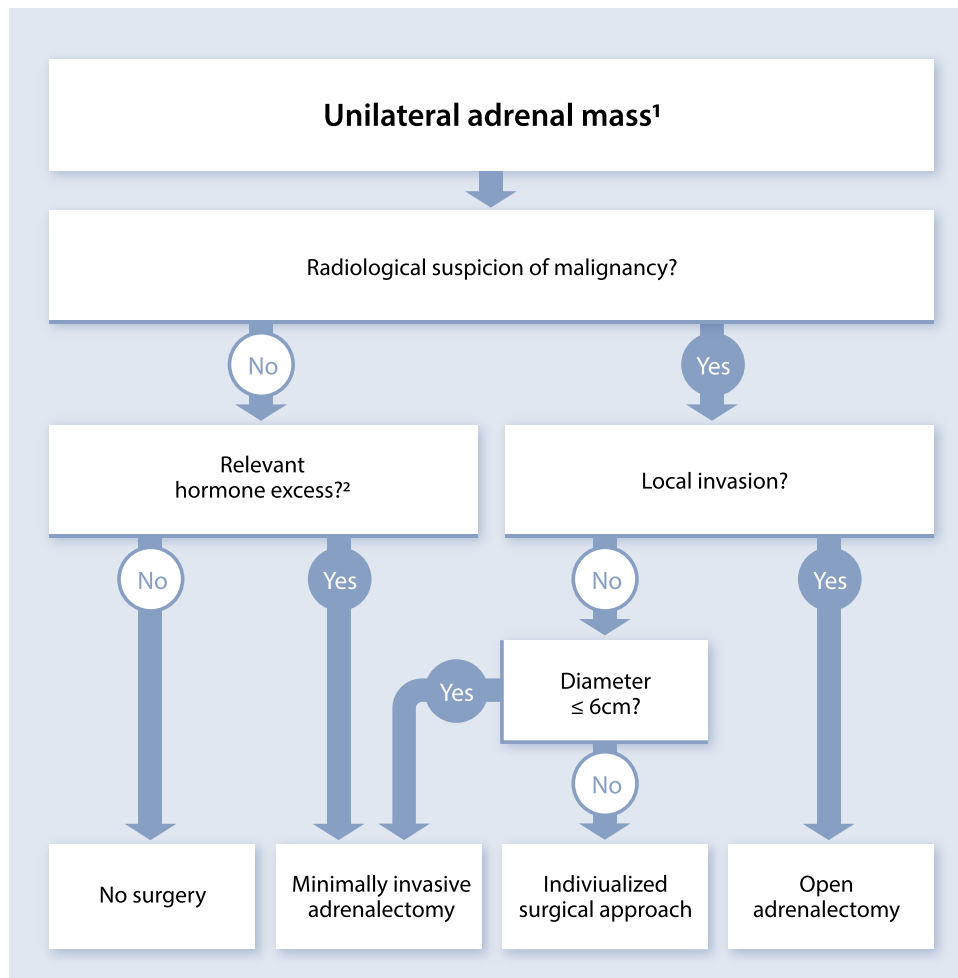


Figure 7. Flow-chart on the management of adrenal masses considered for surgery¹. ¹All patients considered for surgery should be discussed upfront in a multidisciplinary expert team meeting (see R1.1). ²In patients with MACS, an individualized decision-making process is required (see Section 5.3 for details).

feel increasingly insecure of the diagnosis, but again an individualized approach was deemed most appropriate.

- R.4.3 If surgery is indicated for a benign adrenal mass causing hormone excess (including MACS), we recommend that a minimally invasive approach is used (⊕○○○).

Reasoning

Benign adrenal masses causing MACS are usually <6 cm and can safely be removed by a minimally invasive surgical approach, which causes the least patient morbidity compared to an open approach. In the unusual circumstance where such an adrenal tumor is sufficiently large to cause concern about the possibility for removal by a minimally invasive approach, consultation by a very experienced center is advisable.

- R.4.4 We suggest that minimally invasive adrenalectomy is performed by an expert high-volume adrenal surgeon in patients with unilateral adrenal masses with radiological findings suspicious of malignancy (R.2.4-2.6) and a

diameter ≤6 cm, but without evidence of local invasion (⊕○○○).

- R.4.5 We recommend open adrenalectomy is performed by an expert high-volume adrenal surgeon for unilateral adrenal masses with radiological findings suspicious of malignancy and signs of local invasion (⊕○○○).
- R.4.6 We recommend discussion of an individualized surgical approach by an expert high-volume adrenal surgeon in patients that do not fall in one of the above-mentioned categories in a multidisciplinary expert team meeting (⊕○○○).

Reasoning

The main clinical concern of a unilateral adrenal mass, which is suspected to be malignant, is adrenocortical carcinoma. For adrenocortical carcinoma without metastases, surgery is the most important single therapeutic measure. Thus, the expertise of the surgeon is of major importance. Although there is limited evidence about a specific number of operations per year to define such experience and expertise, based on the available evidence,^{155,192,245-249} the panel believes that a minimal annual workload of 12

adrenalectomies/year seems to be minimally required to ensure sufficient experience in adrenal surgery, but >20 adrenalectomies/year are desirable for those involved in surgery for potentially malignant tumors. Furthermore, for suspected adrenocortical carcinoma specific expertise in oncological surgery is required. In general, centralization of adrenalectomies especially in patients with suspected malignant lesion should be aimed at.

As summarized above (Section 4.3), there are 14 publications on surgery for localized adrenocortical carcinoma comparing minimally invasive versus open adrenalectomy, each with more than 10 patients per group.^{154-163,165-167,250} These studies are, however, hampered by methodological flaws, and importantly none was randomized. Nevertheless, based on these data and the clinical experience of the guideline group members, it was judged that minimally invasive adrenalectomy may be justified for tumors with radiological signs of malignancy but only where there was no evidence of local invasion and when surgery is performed by an expert surgeon with extensive experience in surgery for adrenocortical carcinoma. For this approach, the groups were divided on the size cutoff with 3 voting for 5 cm cutoff, 7 for 6 cm, and 2 abstaining. These sizes were selected in the belief that minimally invasive adrenalectomy is feasible without rupture of tumor capsule (a major risk factor for recurrence) and is beneficial for the patient (eg, less pain, shorter hospital stay). However, with increasing tumor size risk of tumor capsule rupture may increase. If during surgery there is a risk of tumor capsule rupture, conversion to open procedure should be performed. We acknowledge that the cutoff of 5-6 cm for minimally invasive vs open adrenalectomy is not based on good evidence from clinical studies, and we recognize that minimally invasive adrenalectomy for tumors <6 cm is common practice in most centers. However, this cutoff by no means indicates that every tumor smaller than 5-6 cm has to undergo minimally invasive adrenalectomy and every tumor larger than 5-6 cm open adrenalectomy. We are convinced that in many cases an individualized decision process is required to find the best surgical approach for a given patient. This is also true for all patients that do not fall in one of the categories described in R.4.2-4.5. Other data point the importance of adequate lymphadenectomy for adrenocortical carcinoma to improve survival,²⁵¹⁻²⁵³ and the potential technical improvements that may be afforded by robotic approaches,^{164,254,255} but these approaches require further validation.

There are no sufficiently powered studies published on the best approach to patients with stage III adrenocortical carcinoma (local invasion, lymph nodes metastases, or tumor thrombus in the renal vein or vena cava). However, the guideline group unanimously voted for open adrenalectomy as standard procedure for this stage of disease, in line with current clinical practice.²⁵⁶⁻²⁵⁸

- R.4.7 We recommend perioperative glucocorticoid treatment at surgical stress doses in all patients undergoing surgery and a preoperative morning serum cortisol >50 nmol/L (1.8 µg/dL) after a 1 mg overnight dexamethasone test.
- R.4.8 We suggest that patients with MACS (similarly to patients with adrenal Cushing's syndrome) that underwent surgery should be followed by an endocrinologist until recovery of hypothalamic-pituitary-adrenal axis function has been documented.

Reasoning

MACS may lead to adrenal insufficiency after removal of the adrenal source of cortisol. The likelihood is greater the higher the cortisol post DST and the lower the plasma ACTH (or serum DHEA-S). However, it is well documented that also patients with incompletely suppressed ACTH might develop postoperative adrenal insufficiency²⁵⁹⁻²⁶¹ and in contrast this is not true for all patients with MACS. Due to this uncertainty, the group is clearly in favor of intra- and postoperative glucocorticoid replacement, preferably by hydrocortisone in patients with an adrenal tumor and lack of suppression of serum cortisol on dexamethasone testing. This should follow the suggestions for major stress dose replacement as per international guidelines.²⁶² Postoperatively, the glucocorticoid dose should be tapered individually by a physician experienced in this clinical scenario. Glucocorticoid therapy should not be stopped until documentation of HPA axis recovery. Since not all patients develop postoperative adrenal insufficiency a first analysis should take place within the first 6 weeks after surgery. Some of these patients may experience a severe glucocorticoid withdrawal syndrome after adrenalectomy for MACS,^{263,264} another reason for monitoring by a physician experienced in postoperative management of patients with cortisol excess.

The panel recognized, however, that some highly experienced centers may perform adrenal surgery without glucocorticoid cover; in this circumstance, the patient's clinical status in the peri- and postoperative period must be even more closely monitored as must the biochemical parameters of the hypothalamus pituitary adrenal axis.

5.5 Follow-up of patients not undergoing adrenal surgery after initial assessment

- R.5.1 We recommend against further imaging during follow-up in patients with an adrenal lesion with clear benign features on imaging studies (⊕⊕⊕○).

Reasoning

Since the 2016 recommendations (based on more than 2300 patients included in follow-up studies^{168,265}), 5 additional follow-up studies including 853 patients have been published.^{32,180-182} The majority of incidentalomas with typical features of adenomas on initial imaging studies are roughly stable in size although spontaneous and slow increases and decreases in size have been described. Importantly, to date, no series reported the occurrence of an adrenal malignancy in these patients regardless of the size of the adrenocortical adenomas. Therefore, the panel was unanimously against repeating imaging investigations if the initial work-up is unequivocally consistent with a benign lesion. We also removed the cutoff for tumor size of 4 cm that was included in the recommendation of 2016.

- R.5.2 In patients with an indeterminate adrenal mass (by imaging), opting not to undergo adrenalectomy following initial assessment, we suggest one repeat noncontrast CT or MRI after 6-12 months to exclude significant growth (⊕○○○). We suggest surgical resection if the lesion enlarges by more than 20% in maximum diameter (in addition to at least a 5 mm increase in maximum diameter) during this period. If there is growth of the lesion below this threshold, additional imaging again after 6-12 months might be considered.

Reasoning

Contrary to benign adrenal tumors that may exhibit a slow growth with time, malignant adrenal lesions (mostly adrenocortical carcinoma and metastases) are mostly characterized by a rapid growth within months.^{209,210,212} Consequently, the panel recommends performing follow-up imaging studies in adrenal incidentaloma in which the benign nature cannot be established with certainty at initial evaluation, in order to recognize a rapidly growing mass.

Lack of growth of an adrenal mass over a period of 6-12 months makes a malignant mass unlikely while surgery is recommended if significant rapid growth is observed. There is no generally accepted definition of significant growth of an adrenal tumor. Therefore, we proposed in our last guidelines⁶⁵ already the above mentioned cutoff adapting the RECIST 1.1 criteria.²⁶⁶

The panel is aware that there are exceptional cases of malignant adrenal tumor without significant growth for several years.^{267,268} However, this can be considered a rare exception and does not justify following all patients with an adrenal mass with repeated imaging over years. However, in case there is some measurable growth (<20%) that does not qualify for the above-mentioned criteria, additional follow-up imaging seems justified; although data supporting this approach are lacking.

- R.5.3 We recommend against repeated hormonal work-up in patients with hormonal work-up results within the reference range at initial evaluation unless new clinical signs of endocrine activity appear or there is worsening of comorbidities (eg, hypertension, type 2 diabetes) (⊕⊕○○).

Reasoning

Studies with a total of more than 3000 patients with non-functioning adrenal incidentaloma confirm that the risk of developing clinically relevant overt hormonal excess is extremely low: 0.0%-0.6% for Cushing's syndrome, 0.0%-1.6% for primary aldosteronism, and 0.0%-2.1% for pheochromocytoma. See Section 4.4.

The analysis of published studies suggests that the development of MACS occurs in approximately 5% of patients (see Figure S4). However, some panelists felt that this number is higher in their clinical experience. Nevertheless, due to the unlikely occurrence of MACS and other relevant hormonal excess, and the risk of false positive results of the 1 mg DST²²¹⁻²²⁴ the panel voted against systematic follow-up hormonal investigations in patients with nonfunctioning adrenal incidentalomas at initial evaluation. However, in case of significant change in comorbidities potentially attributable to MACS, a 1-mg dexamethasone test should be repeated.

- R.5.4 In patients with MACS who do not undergo an adrenalectomy, we recommend only annual reassessment of comorbidities potentially attributable to cortisol (⊕⊕○○). For this purpose, we suggest that discharge from specialized endocrine follow-up be considered and that monitoring of comorbidities potentially attributable to cortisol could be undertaken by primary health care providers, if adequate surveillance for comorbidities is available in the community (⊕○○○). If these comorbidities develop or worsen, referral to an endocrinologist is suggested to reassess the endocrine status and reconsider the potential benefit of intervention.

Reasoning

As elaborated in Section 5.3, the panel considers MACS as a condition associated with several comorbidities (Table 5). However, as discussed above, it is extremely rare that patients with MACS will develop overt Cushing's syndrome during follow-up. Therefore, the panel voted against routine endocrine reevaluation of the hypothalamic-pituitary axis function but recommends annual clinical follow-up of comorbidities potentially attributable to cortisol in patients with MACS and, in whom an initial decision against surgery was made. For this annual evaluation the following measures seems reasonable: HbA1c, blood pressure (ideally as ambulatory measurement), LDL and HDL cholesterol, triglycerides, and body weight. Due to the frequency of MACS in this cohort and the fact that the follow-up of these nonspecific comorbidities (such as hypertension, obesity, impaired glucose tolerance) is usually performed by general practitioners and primary health care providers, we would consider discharging the patient from specialized endocrine follow-up. We strongly encourage close collaboration between endocrinologists and primary health care providers and the provision of pertinent information of patients, to consider referral to an endocrinologist if these comorbidities worsen or if they or even signs of overt Cushing's syndrome newly arise. A specialized clinical and endocrine reevaluation may be performed at this time to reconsider therapeutic options such as appropriate symptomatic treatment or surgical removal of the adrenal incidentaloma.

5.6. Special circumstances

5.6.1 Patients with bilateral adrenal incidentalomas

- R.6.1.1 We recommend that for patients with bilateral or multiple adrenal masses each adrenal lesion is assessed at the time of initial detection according to the same imaging protocol as for unilateral adrenal masses to establish whether each nodule is benign or malignant.

Reasoning

In most cases bilateral adrenal masses represent benign bilateral adrenocortical disease: either bilateral adenomas, macronodular hyperplasia, or distinct bilateral nodules with normal or atrophic cortex intervening. However, the possibility of metastases (especially in patients with known extra-adrenal malignancy), adrenal lymphoma or bilateral pheochromocytomas should also be considered. Moreover, bilateral adrenal masses may represent cooccurrence of different entities, such as adenoma, pheochromocytoma, cyst, myelolipoma, adrenocortical carcinoma, etc. Therefore, the best approach is to separately characterize each lesion following the recommendations in R.2.2-R.2.6.

- R.6.1.2 We recommend that all patients with bilateral adrenal incidentalomas should undergo clinical and hormonal assessment identical to that in patients with unilateral adrenal incidentaloma.
- R.6.1.3 We suggest approaching bilateral disease according to the following 4-option schema based on the results of the imaging and hormonal work-up (Table 6; Figure 8) (1) bilateral (macronodular) hyperplasia, (2) bilateral adrenal adenomas, (3) 2 morphologically similar, but nonadenoma-like adrenal masses, and (4) 2

Table 6. Sub-differentiation of bilateral adrenal incidentalomas.

	Bilateral hyperplasia	Bilateral adrenal adenomas	Two morphological similar adrenal masses (but indeterminate by imaging and hormone analysis)	Two morphological different adrenal masses
Imaging work-up	There are 2 main forms of hyperplasia, a diffuse type without distinct nodules and a macronodular type, in which both adrenals typically harbor more than one nodule (usually with unenhanced HU < 10) and the remaining adrenals are usually thickened.	Typically, both adrenals harbor one distinct/unambiguous adenoma (unenhanced HU < 10) and the remaining adrenal limbs are normal or thin.	Unenhanced and/or enhanced HU in CT are typically similar for the different masses (as is appearance in MRI or FDG-PET) and imaging characteristics are not typical for an adenoma.	The appearance of the adrenal masses is clearly different in unenhanced and/or enhanced CT, MRI or FDG-PET, but at least one of them has characteristics not typical of an adenoma.
Hormonal work-up (in addition to standard diagnostic work-up)	If congenital adrenal hyperplasia is suspected, consider measurement of basal 17-OH progesterone to diagnose (or exclude) CAH, which may be especially important to consider in case of signs, symptoms or biochemistry of hyperandrogenemia.	In case of signs, symptoms or biochemistry of hyperandrogenemia, additional measurement of basal 17-OH progesterone should be considered to exclude CAH.	In infiltrative masses (eg, lymphomas, metastases) or bilateral hemorrhages, exclusion of adrenal insufficiency is required.	Standard hormonal work-up is sufficient (see Section 5.3).
Clinical consequences	If CAH is excluded, consider primary bilateral macronodular adrenal hyperplasia (PBMAH) as diagnosis. In the presence of multiple modules and ACTH-independent MACS, genetic testing for germline pathogenic <i>ARMC5</i> variants should be offered ^a . In patients with MACS, unilateral adrenalectomy of the dominant side might be considered using an individualized approach considering age, degree of cortisol excess, general conditions and patient preferences.	In patients with MACS, management should follow the recommendations given in R.3.3-9. In selected patients, unilateral adrenalectomy of the dominant lesion might be considered using an individualized approach considering age, degree of cortisol excess, general conditions and patient preferences.	In pheochromocytomas, genetic testing for PPGL-associated genes is mandatory. If malignant lesions are suspected, a biopsy should be considered.	Investigation of underlying etiology needed.

^aPatients with pathogenic *ARMC5* variants have typically a more severe phenotype and deserve special attention. Abbreviations: HU, Hounsfield unit; CAH, congenital adrenal hyperplasia; MACS, mild autonomous cortisol secretion.

morphologically different adrenal masses. In patients who do not fall in one of these categories, an individualized management plan is needed.

- R.6.1.4 For patients with bilateral hyperplasia without autonomous cortisol secretion, we suggest measuring 17-hydroxyprogesterone to exclude CAH due to 21-hydroxylase deficiency.
- R.6.1.5 For patients with bilateral (macronodular) hyperplasia or bilateral adenomas, we recommend assessment of comorbidities that are potentially attributable to MACS.
- R.6.1.6 In patients with bilateral metastases, lymphoma, infiltrative inflammatory disease, and hemorrhages, we recommend assessment for adrenal insufficiency.

Reasoning

Hormonal excess in patients with bilateral adrenal masses may originate either from one of the lesions or bilaterally. Cushing's syndrome, primary aldosteronism, and

pheochromocytoma(s) may all be encountered. For the clinical assessment of these entities we refer to guidelines of other societies.⁶¹⁻⁶³

Due to the fact that some of the above-mentioned entities require specific management, it is usually required to get advice from an experienced center with an adrenal multidisciplinary expert team meeting (see R.1.1). In general, it is helpful to discriminate the 4 subcategories (Table 6). A thorough analysis of the available imaging is the first important step. We have provided typical examples in Figure 8. With this approach some specific hormonal tests can be restricted to a limited number of patients. For example, 17-hydroxyprogesterone is only needed in patients with bilateral hyperplasia and testing of adrenal insufficiency is only necessary in patients with large and/or infiltrative bilateral masses (eg, lymphomas, metastases) or bilateral hemorrhages. For example, in a study of 579 patients with adrenal metastases, bilateral adrenal metastases were found in 24% of patients at the time of initial presentation,

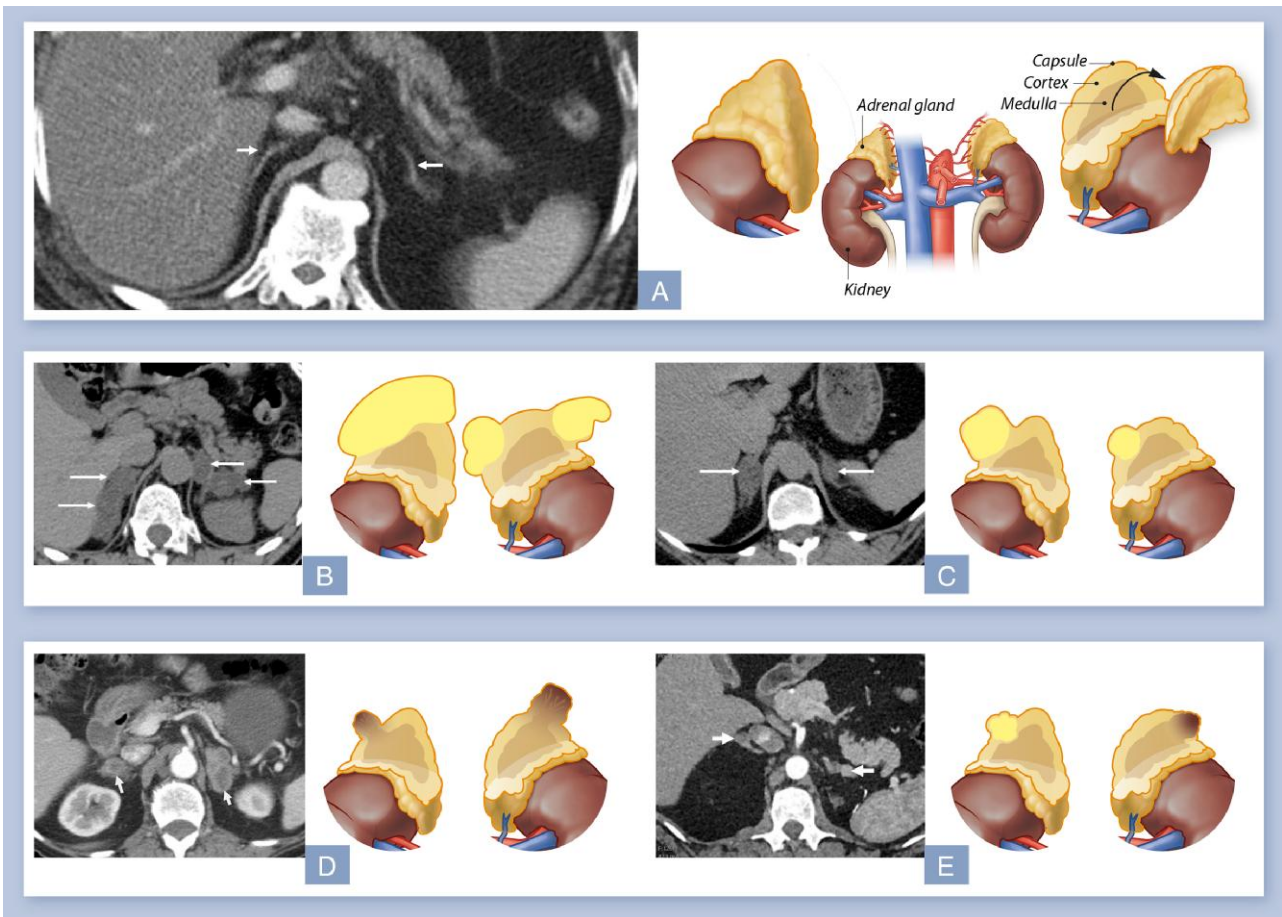


Figure 8. Typical examples of bilateral adrenal incidentalomas. On the left side a typical CT image is depicted and on the right side a corresponding cartoon. A) Bilateral normal smooth adrenal contours (white arrows) with no focal nodules or enlargement. B) Bilateral adrenal hyperplasia with multiple nodules (white arrows) and expansion of the intervening left adrenal tissue (arrow head). C) Bilateral adrenal adenomas. D) Two morphologically similar, but nonadenoma-like adrenal masses: bilateral adrenal metastases from bronchogenic carcinoma. E) Two morphologically different adrenal masses: right: lipid-rich adenoma, left pheochromocytoma.

and 43% of patients had bilateral metastases at the end of follow up. In this study, despite a nonuniform testing, 12.4% of patients with bilateral lesions were diagnosed with primary adrenal insufficiency. The prevalence of primary adrenal insufficiency was 20% in patients with adrenal metastases >4 cm.¹¹ To assess adrenal function, measurement of morning serum cortisol and plasma ACTH is a reasonable first step. In case of adrenal insufficiency, cortisol is low and plasma ACTH is clearly elevated. In uncertain cases, a synacthen test could be performed.²⁶²

Bilaterally enlarged adrenal glands can also be caused by underlying CAH; this can be screened by 17-hydroxyprogesterone (for details²⁶⁹). However, increased levels of 17-hydroxyprogesterone may also represent increased secretion of steroid precursors from the lesion(s)^{270,271} especially in malignant tumors or in bilateral macronodular adrenal hyperplasia. In these cases, low/suppressed ACTH levels are useful to distinguish from CAH.

MACS is more frequent in patients with bilateral hyperplasia or adenomas than in unilateral adenomas.^{12,40} In patients with primary bilateral macronodular adrenal hyperplasia and MACS, the number of nodules correlate with the likelihood of a pathogenic germline *ARMC5* variant.²⁷² Patients with pathogenic *ARMC5* variants typically have a more severe phenotype and more frequently develop signs of overt

Cushing's syndrome.²⁷³ Thus, they deserve special attention and potentially more proactive monitoring and therapeutic management.

In patients with detected pathogenic germline alterations, genetic counseling of first-degree relatives should be offered.

- R.6.1.7 In patients with bilateral hyperplasia or bilateral adenomas and MACS, we suggest individualization of specific treatment options based on age, sex, degree of cortisol autonomy, general condition, comorbidities, and patient preference.
- R.6.1.8. We suggest against bilateral adrenalectomy in patients without clinical signs of overt Cushing's syndrome.

Reasoning

As mentioned above, MACS is more frequently encountered in patients with bilateral adrenal incidentalomas, compared to those with unilateral lesions,^{12,40} but there is no published evidence that these patients should be managed differently. Bilateral adrenalectomy is rarely indicated except when there is evidence of overt Cushing's syndrome. Bilateral adrenalectomy is associated with higher morbidity compared to

unilateral surgery; the patient is dependent on lifelong adrenal replacement therapy and at risk for life-threatening adrenal crises.

In bilateral macronodular adrenal hyperplasia there is limited evidence of beneficial effects of unilateral adrenalectomy.^{148,274} In most published studies excision of the largest lesion was performed, based on observations that the size of the adrenal lesion correlates with the degree of cortisol excess.²⁷⁴ Adrenal venous sampling may aid in the lateralization of cortisol excess but the data are very weak.^{273,275-277} Adrenal insufficiency can occur and last for months/years after unilateral adrenalectomy and should be evaluated for and appropriately treated. Monitoring for recurrence of MACS from the remaining abnormal adrenal gland is important. Due to the limited available evidence, an individualized approach, considering age, degree of cortisol excess, general condition, comorbidity status and patient's preference is reasonable. However, when bilateral surgery is potentially indicated, adrenal-sparing surgery might be considered.²⁷⁸

An alternative approach could be medical therapy. However, the evidence for such an approach is still too low to give clear guidance, but in selected patients steroidogenesis inhibitors can be considered.

A number of patients will have evidence of the presence of aberrant receptors, but routine assessment by the complex testing^{34,279-284} that is needed to establish the presence of these receptors is hard to justify based on the fact that in the majority of patients long-term management will not be based on knowledge of receptor activity, and therefore, we do not advise use of such testing in routine clinical practice.

In patients with bilateral pheochromocytomas, adrenal-sparing surgery might be considered depending on the underlying genetic predisposing finding.^{285,286} Genetic testing is strongly advised in these patients.

5.6.2 Adrenal incidentalomas in young or elderly patients

- R.6.2.1 We recommend urgent assessment of an adrenal mass in pregnant women and individuals <40 years of age, because of a higher likelihood of malignancy and clinically significant hormone excess.
- R.6.2.2 We suggest the use of MRI rather than CT in children, adolescents, and pregnant women if dedicated adrenal imaging is required.
- R.6.2.3 We suggest surgical resection if an adrenal mass is indeterminate on imaging in children, adolescents, pregnant women and adults <40 years of age.
- R.6.2.4 We recommend that investigation and management of patients with poor general health and a high degree of frailty be kept in proportion to potential clinical gain.

Reasoning

The incidence of adrenal incidentaloma shows clear variation with age, with the majority of patients presenting in the fifth to seventh decade of life. Overall incidence of adrenal incidentaloma in a population undergoing routine imaging not related to suspected adrenal disease is reported as 1%–4%.^{2,21,23,24,68,287} While 10% or more of individuals older than 70 years harbor an adrenal mass detectable upon imaging or autopsy, adrenal nodules in individuals <40 years are much less prevalent and are a rarity in children and young adults. Consequently, work-up in young patients including

pregnant women has to be pursued with urgency as the risk of malignancy and prevalence of relevant hormone excess in this cohort is much higher. Due to this higher pretest probability of a malignant lesion, time-consuming diagnostic procedures should be avoided and surgery, if indicated, should not be significantly delayed. In contrast to the typical patient with adrenal incidentaloma (usually > 50 years), we would consider 1 follow-up imaging after 12 months also for a presumably benign adrenal mass in very young patients.

Conversely, a smaller adrenal incidentaloma in an elderly patient without history of extra-adrenal malignancy can be assumed to have a very low pretest probability of malignancy. Thus work-up in elderly patients only needs to be expedited if there are clear signs of suspicion of malignancy and the extent of imaging work-up should be kept in proportion to the clinical performance status of the individual and the expected clinical gain of further work-up in an affected patient. There is also increasing evidence that cortisol after dexamethasone is more frequently elevated in elderly,^{12,40} but the clinical consequences appear less significant in this cohort.⁴⁰

As radiation safety is even more important in the young patient, we suggest MRI as the preferred imaging technique in this age group. However, adapted low-dose unenhanced CT protocols can limit radiation exposure and can be considered as an alternative (especially if the availability of MRI is limited or cannot be tolerated).

5.6.3 Patients with a newly diagnosed adrenal mass and a history of extra-adrenal malignancy

General remarks:

In principle, for adrenal masses in patients with known extra-adrenal malignancy the same recommendations apply as described above (Figure 9). However, in this situation, it is particularly important to consider the different pretest probabilities of the nature of the lesion and the life expectancy of the patient.

In patients with underlying extra-adrenal malignancy and an indeterminate adrenal mass, studies revealed a high rate of malignancy, up to 70%. Although age specific subgroup data are not available, it can be assumed that older patients have a higher likelihood of co-existent benign adenomas. Conversely, younger patients with an underlying malignancy are more likely to have a metastasis.

- R.6.3.1 We recommend measurement of plasma or urinary metanephrines to exclude pheochromocytoma in patients with extra-adrenal malignancy with an indeterminate mass, even if the adrenal mass is likely to be a metastasis. We suggest additional hormonal work-up based on an individualized approach.

Reasoning

It is almost impossible to distinguish a pheochromocytoma from a metastasis in the adrenal by conventional imaging (including FDG-PET/CT). Furthermore, pheochromocytomas can lead to life-threatening complications, especially in the context of medical interventions (surgery, biopsies etc.).^{62,288,289} Additional hormonal work-up should depend on the stage of the extra-adrenal malignancy and life expectancy. However, clinicians should be aware that the evidence of adrenal hormone excess indicating that the mass is a

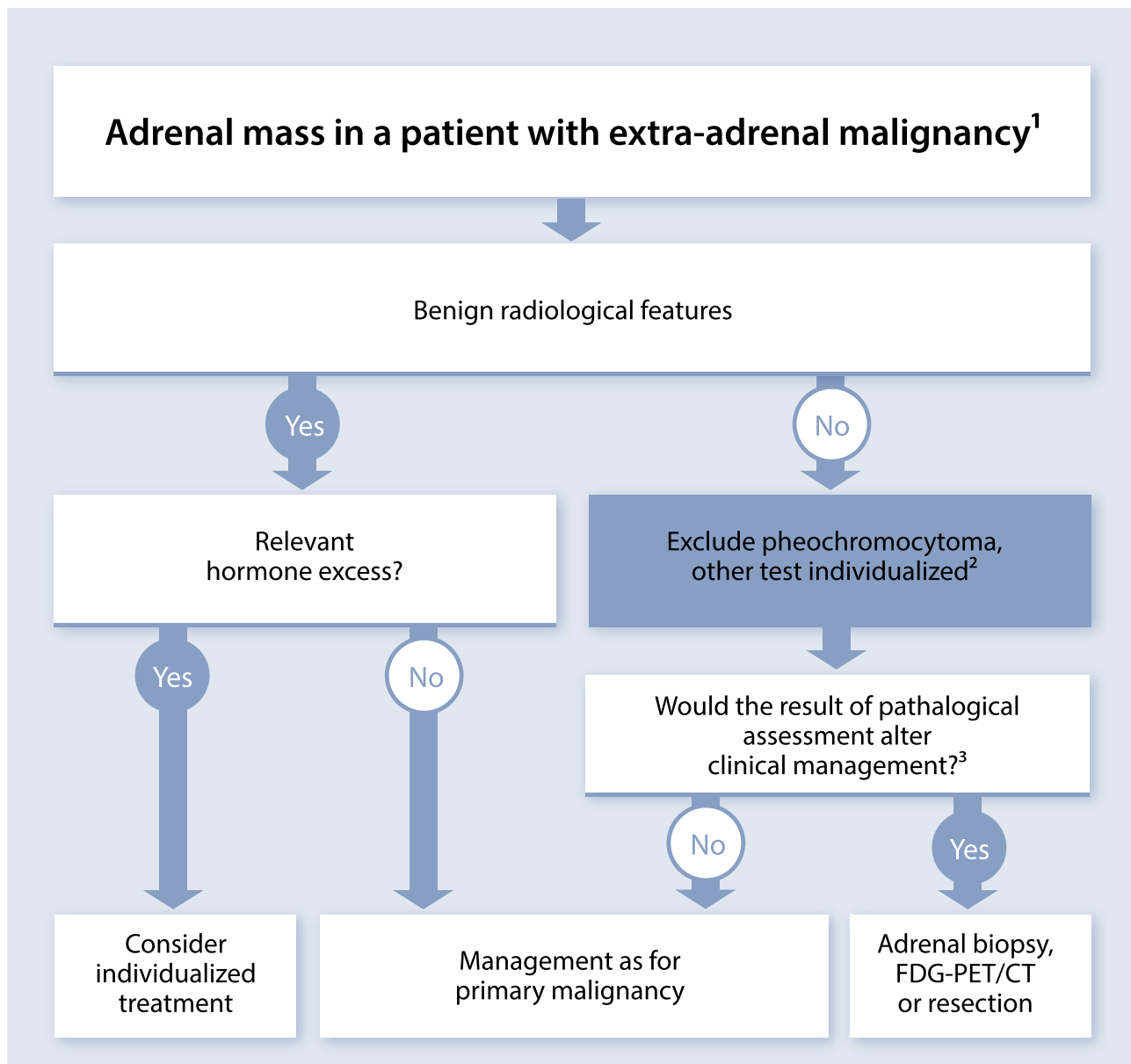


Figure 9. Evaluation of patients with adrenal mass and known extra-adrenal malignancy. ¹Always take life expectancy in consideration. ²If there is hormone excess, treat individualized. ³FDG-PET/CT should be considered to exclude other metastatic deposits in patients with no other obvious metastatic lesions for whom surgical removal of the lesion is an option.

primary adrenal lesion can influence management of the extra-adrenal malignancy.

- R.6.3.2 We recommend that in patients with a history of extra-adrenal malignancy adrenal lesions characterized as benign by noncontrast CT require no further specific adrenal imaging follow-up.
- R.6.3.3 In patients with a history of extra-adrenal malignancy, strong FDG uptake in the adrenal gland(s) on PET-CT is suggestive of metastasis. In case of moderate or no FDG uptake, further work-up with at least unenhanced CT is recommended.

Reasoning

Although some studies indicate that few adrenal metastases may have $HU \leq 20$,^{8,76} the vast majority of adrenal

masses with $HU \leq 20$ are benign and imaging that is being used for investigation and follow-up of the underlying malignancy is usually sufficient for these patients. As mentioned in R.2.4-6, FDG-PET/CT is—despite several limitations—currently probably the most reliable imaging method in the assessment of an adrenal mass that is indeterminate by unenhanced CT. Although there are few malignant lesions that are FDG-negative, especially renal cancer, FDG-uptake will be high in most adrenal metastases.^{50,51,290,291} However, clinicians have to be aware that also a subset of benign tumors (especially if they are endocrine active) are FDG-positive.⁵¹ If the FDG-PET/CT was performed with only a contrast-enhanced CT in venous phase, an unenhanced CT (or additional imaging methods; see Table 4) might be needed to determine if the lesion is benign or malignant.

- R.6.3.4 For indeterminate lesions in patients with a history of extra-adrenal malignancy, in whom the clinical management will be altered by the demonstration that the adrenal lesion is malignant, we suggest performing either an FDG-PET/CT (if not done already), surgical resection or a biopsy (see also R.6.3.5). In all other patients, we recommend imaging follow-up at the same interval as imaging for the primary malignancy.

Reasoning

In many patients with advanced extra-adrenal malignancy (eg, with multiple metastases) the knowledge of the origin of the adrenal mass will not alter the clinical management of the patient. If, however, clinical management would be altered by the demonstration that the adrenal lesion is a metastasis, then every effort should be made to allow this discrimination. If a unilateral adrenal mass is potentially the only metastasis and if resection of this metastasis seems to be reasonable from an oncological point of view, then surgery should be considered. Regarding biopsy, we refer to the criteria provided in R.6.3.5.

- R.6.3.5 We recommend that 3 key criteria be fulfilled before adrenal biopsy is considered: (1) the lesion is hormonally inactive (in particular, a pheochromocytoma has been excluded), (2) the lesion has not been conclusively characterized as benign by imaging, and (3) clinical management of the patient would be altered by knowledge of the histology.

Reasoning

Adrenal biopsy may present with a significant nondiagnostic rate and a potential for complications⁸⁶ (see also Section 4.1.2). Biopsy is only recommended for masses not characterized as benign on imaging and where a biopsy result would affect clinical treatment decisions. In patients with no other obvious metastatic lesions and when surgical removal of the lesion is an option, FDG-PET/CT should be considered in order to exclude metastases outside the adrenal that were not visualized by CT or MRI. Adrenal biopsy has lower diagnostic performance for adrenocortical carcinoma and, therefore, is not recommended in this setting.^{86,87} If a biopsy is necessary, this should be performed by a specialist interventional radiologist/physician. In uncertain cases, it is reasonable to discuss upfront with the pathologist how much material is needed to perform a complete diagnostic work-up (eg, in lymphoma or sarcoma). Reading of the biopsy should be done by an experienced pathologist.

- R.6.3.6 We recommend assessment of residual adrenal function in patients with large bilateral metastases.

Reasoning

Bilateral adrenal metastases can lead to primary adrenal insufficiency in ~12% of patients.¹¹ Thus, in all patients with bilateral metastases, primary adrenal insufficiency should be considered and clinically evaluated. The first step is measurement of morning serum cortisol and plasma ACTH. In case of primary adrenal insufficiency, plasma ACTH is elevated and serum cortisol is low. In uncertain cases, a synacthen test could be performed.²⁶²

If only one adrenal metastasis is present, primary adrenal insufficiency is extremely unlikely and usually no specific assessment of adrenal reserve is required.

6. Future directions and recommended research

In 2016, we formulated several research questions for future studies.⁶⁵ Although some of these issues have been addressed and for some recommendations the level of evidence could be increased, only few questions have been conclusively answered. Therefore, we still see the need for clinical trials in all 4 areas addressed in the guideline (see Section 3.5).

Among many important research questions, we selected 10 as particularly important. All of them can only be answered in a collaborative interdisciplinary manner.

1. The value of unenhanced CT is now well established. However, at least a third of adrenal incidentaloma have HU > 10. Therefore, large cohort studies are needed in patients with an adrenal incidentaloma and unenhanced HU > 10 to investigate the most suitable “second-line imaging methods” to determine if an adrenal mass is benign or not. It will be crucial to establish a definitive diagnosis either by histopathology or by long-term follow-up (> 1 years). In this context, radiomics and other artificial intelligence tools may be helpful.
2. Recently, urine steroid metabolomics for noninvasive and radiation free detection of a malignant “steroid fingerprint” in patients with adrenocortical carcinoma has been prospectively validated.⁸ After clinical routine implementation, real-world data are needed to confirm the value of this method.
3. In the last 2 years, large, long-term studies demonstrated an association of MACS with increased morbidity and mortality.^{12,39,40,237} However, all these studies were retrospective or this association not the primary endpoint of the study. Thus, prospective studies on “hard” cardiovascular endpoints, cancer incidence, and mortality are still lacking, but they are required to define the absolute risk associated with MACS beyond classical risk factors like diabetes, hypertension, and smoking.
4. The above-mentioned studies cannot prove causality between MACS and morbidity and mortality. Recently, a small randomized trial is published,¹⁴⁵ and other trials assessing the outcome of surgery or medical therapies are underway. However, more methodologically robust randomized trials are needed on the potential benefit of surgery or medical treatment in patients with MACS. Although a control group with sham operation or placebo would be ideal, we believe that this is unrealistic and might not be required. It seems to be more important to define surrogate endpoints (eg, hypertension or type 2 diabetes) that can be well controlled (including standardized treatment regimens) throughout the study. Furthermore, the duration of the study has to be sufficiently long (minimum 12 months, better 2 or 3 years), especially in trials with adrenalectomy, because the removal of cortisol-producing cells might lead in all humans to some reduction of blood pressure or glucose level. Ideally, these randomized trials would include—after the actual randomized phase—a long-term

observational period to collect data on “hard” cardiovascular endpoints, cancer incidence, and especially mortality.

5. The association between MACS and osteoporosis is not yet well established. Thus, large prospective cohorts are required to study the performance of noninvasive radiological tools to accurately assess the impact of MACS on bone (including bone microarchitecture) and to evaluate the fracture risk in incidentalomas associated with MACS.
6. Currently, we rely on the diagnosis of MACS on the 1mg-DST, which has several caveats as discussed above. Very few data are available on whether a patient’s assignment to nonfunctioning tumor or MACS remains constant over the long-term. Studies with repeated DST must provide an answer here.
7. Along the same lines, new biomarkers to identify patients with clinically relevant cortisol excess would be important.
8. A prospective study (minimally invasive and/or robotic vs open surgery) in patients with potentially malignant adrenal mass without preoperative evidence of local invasion and metastases is desired to learn which surgical approach is the most suitable one for this patient cohort.
9. We propose a long-term study with annual biochemical work-up of patients with adrenal incidentalomas to clarify if such a long-term hormonal assessment is justified. This study will also help to define the true incidence of relevant diseases like adrenocortical carcinoma and pheochromocytoma among incidentalomas.
10. There is a need for large cohort and prospective studies on quality of life, mental health, cognition, and frailty in patients with adrenal incidentalomas, both nonfunctioning and the ones with MACS.

Acknowledgment

The authors of the guideline would like to thank and acknowledge Mark Sherlock (endocrinologist, Dublin, Ireland), Radu Mihai (surgeon, Oxford, United Kingdom), and Anand Vaidya (endocrinologist, Boston, United States), as well as Elaine Caoili (representative of the Society of Abdominal Radiology) and Pieter De Visschere (representative of the European Society of Urogenital Radiology) for their expert review and advice. In addition, we are grateful for valuable and critical comments of 21 members of the European Society of Endocrinology, the European Network for the Study of Adrenal Tumors or representatives of national endocrine societies. Furthermore, we thank 2 patient representatives who provided valuable feedback for the guideline. The 169 comments of the reviewers as well as our responses are available in [Table S2](#).

Supplementary material

[Supplementary material](#) is available at *European Journal of Endocrinology* online.

Funding

This guideline was sponsored by the European Society of Endocrinology with support by the European Network for

the Study of Adrenal Tumors (ENSAT) and the COST Action “Harmonizing clinical care and research on adrenal tumours in European countries” (HARMONISATION) CA20122 supported by COST (European Cooperation in Science and Technology).

Declaration of interest

See [Table S1](#).

References

1. Ebbelohj A, Li D, Kaur RJ, *et al.* Epidemiology of adrenal tumours in Olmsted county, Minnesota, USA: a population-based cohort study. *Lancet Diabetes Endocrinol.* 2020;8(11):894-902. [https://doi.org/10.1016/S2213-8587\(20\)30314-4](https://doi.org/10.1016/S2213-8587(20)30314-4)
2. Jing Y, Hu J, Luo R, *et al.* Prevalence and characteristics of adrenal tumors in an unselected screening population : a cross-sectional study. *Ann Intern Med.* 2022;175(10):1383-1391. <https://doi.org/10.7326/M22-1619>
3. Hamidi O, Raman R, Lazik N, *et al.* Clinical course of adrenal myelolipoma: a long-term longitudinal follow-up study. *Clin Endocrinol (Oxf).* 2020;93(1):11-18. <https://doi.org/10.1111/cen.14188>
4. Calissendorff J, Juhlin CC, Sundin A, Bancos I, Falhammar H. Adrenal myelolipomas. *Lancet Diabetes Endocrinol.* 2021;9(11):767-775. [https://doi.org/10.1016/S2213-8587\(21\)00178-9](https://doi.org/10.1016/S2213-8587(21)00178-9)
5. Dogra P, Rivera M, McKenzie TJ, *et al.* Clinical course and imaging characteristics of benign adrenal cysts: a single-center study of 92 patients. *Eur J Endocrinol.* 2022;187(3):429-437. <https://doi.org/10.1530/EJE-22-0285>
6. Dages KN, Kohlenberg JD, Young WF, Jr., *et al.* Presentation and outcomes of adrenal ganglioneuromas: a cohort study and a systematic review of literature. *Clin Endocrinol (Oxf).* 2021;95(1):47-57. <https://doi.org/10.1111/cen.14460>
7. Gruber LM, Hartman RP, Thompson GB, *et al.* Pheochromocytoma characteristics and behavior differ depending on method of discovery. *J Clin Endocrinol Metab.* 2019;104(5):1386-1393. <https://doi.org/10.1210/je.2018-01707>
8. Bancos I, Taylor AE, Chortis V, *et al.* Urine steroid metabolomics for the differential diagnosis of adrenal incidentalomas in the EURINE-ACT study: a prospective test validation study. *Lancet Diabetes Endocrinol.* 2020;8(9):773-781. [https://doi.org/10.1016/S2213-8587\(20\)30218-7](https://doi.org/10.1016/S2213-8587(20)30218-7)
9. Ichijo T, Ueshiba H, Nawata H, Yanase T. A nationwide survey of adrenal incidentalomas in Japan: the first report of clinical and epidemiological features. *Endocr J.* 2020;67(2):141-152. <https://doi.org/10.1507/endocrj.EJ18-0486>
10. Iniguez-Ariza NM, Kohlenberg JD, Delivanis DA, *et al.* Clinical, biochemical, and radiological characteristics of a single-center retrospective cohort of 705 large adrenal tumors. *Mayo Clin Proc Innov Qual Outcomes.* 2018;2(1):30-39. <https://doi.org/10.1016/j.mayocpiqo.2017.11.002>
11. Mao JJ, Dages KN, Suresh M, Bancos I. Presentation, disease progression and outcomes of adrenal gland metastases. *Clin Endocrinol (Oxf).* 2020;93(5):546-554. <https://doi.org/10.1111/cen.14268>
12. Prete A, Subramanian A, Bancos I, *et al.* Cardiometabolic disease burden and steroid excretion in benign adrenal tumors : a cross-sectional multicenter study. *Ann Intern Med.* 2022;175(3):325-334. <https://doi.org/10.7326/M21-1737>
13. Cyranska-Chyrek E, Szczepanek-Parulska E, Olejarz M, Ruchala M. Malignancy risk and hormonal activity of adrenal incidentalomas in a large cohort of patients from a single tertiary reference center. *Int J Environ Res Public Health.* 2019;16(10):1872. <https://doi.org/10.3390/ijerph16101872>
14. Stavropoulos K, Imprialos KP, Katsiki N, *et al.* Primary aldosteronism in patients with adrenal incidentaloma: is screening

- appropriate for everyone? *J Clin Hypertens (Greenwich)*. 2018;20(5):942-948. <https://doi.org/10.1111/jch.13291>
15. Mansmann G, Lau J, Balk E, Rothberg M, Miyachi Y, Bornstein SR. The clinically inapparent adrenal mass: update in diagnosis and management. *Endocr Rev*. 2004;25(2):309-340. <https://doi.org/10.1210/er.2002-0031>
 16. Grumbach MM, Biller BM, Braunstein GD, et al. Management of the clinically inapparent adrenal mass ("incidentaloma"). *Ann Intern Med*. 2003;138(5):424-429. <https://doi.org/10.7326/0003-4819-138-5-200303040-00013>
 17. Sherlock M, Scarsbrook A, Abbas A, et al. Adrenal incidentaloma. *Endocr Rev*. 2020;41(6):775-820. <https://doi.org/10.1210/endo/bnaa008>
 18. Kloos RT, Gross MD, Francis IR, Korobkin M, Shapiro B. Incidentally discovered adrenal masses. *Endocr Rev*. 1995;16:460-484.
 19. Barzon L, Sonino N, Fallo F, Palu G, Boscaro M. Prevalence and natural history of adrenal incidentalomas. *Eur J Endocrinol*. 2003;149:273-285. <https://doi.org/10.1530/eje.0.1490273>
 20. Mantero F, Terzolo M, Arnaldi G, et al. A survey on adrenal incidentaloma in Italy. Study group on adrenal tumors of the Italian Society of Endocrinology. *J Clin Endocrinol Metab*. 2000;85:637-644.
 21. Bovio S, Cataldi A, Reimondo G, et al. Prevalence of adrenal incidentaloma in a contemporary computerized tomography series. *J Endocrinol Invest*. 2006;29(4):298-302. <https://doi.org/10.1007/BF03344099>
 22. Benitah N, Yeh BM, Qayyum A, Williams G, Breiman RS, Coakley FV. Minor morphologic abnormalities of adrenal glands at CT: prognostic importance in patients with lung cancer. *Radiology*. 2005;235(2):517-522. <https://doi.org/10.1148/radiol.2352031708>
 23. Reimondo G, Castellano E, Grosso M, et al. Adrenal incidentalomas are tied to increased risk of diabetes: findings from a prospective study. *J Clin Endocrinol Metab*. 2020;105(4):dgz284.
 24. Hammarstedt L, Muth A, Wangberg B, et al. Adrenal lesion frequency: a prospective, cross-sectional CT study in a defined region, including systematic re-evaluation. *Acta Radiol*. 2010;51(10):1149-1156. <https://doi.org/10.3109/02841851.2010.516016>
 25. Barzon L, Scaroni C, Sonino N, Fallo F, Paoletta A, Boscaro M. Risk factors and long-term follow-up of adrenal incidentalomas. *J Clin Endocrinol Metab*. 1999;84:520-526.
 26. Bernini GP, Moretti A, Oriandini C, Bardini M, Taurino C, Salvetti A. Long-term morphological and hormonal follow-up in a single unit on 115 patients with adrenal incidentalomas. *Br J Cancer*. 2005;92(6):1104-1109. <https://doi.org/10.1038/sj.bjc.6602459>
 27. Fagour C, Bardet S, Rohmer V, et al. Usefulness of adrenal scintigraphy in the follow-up of adrenocortical incidentalomas: a prospective multicenter study. *Eur J Endocrinol*. 2009;160(2):257-264. <https://doi.org/10.1530/EJE-08-0299>
 28. Libe R, Dall'Asta C, Barbetta L, Baccarelli A, Beck-Peccoz P, Ambrosi B. Long-term follow-up study of patients with adrenal incidentalomas. *Eur J Endocrinol*. 2002;147:489-494. <https://doi.org/10.1530/eje.0.1470489>
 29. Terzolo M, Bovio S, Pia A, et al. Midnight serum cortisol as a marker of increased cardiovascular risk in patients with a clinically inapparent adrenal adenoma. *Eur J Endocrinol*. 2005;153(2):307-315. <https://doi.org/10.1530/eje.1.01959>
 30. Terzolo M, Osella G, Ali A, et al. Subclinical Cushing's syndrome in adrenal incidentaloma. *Clin Endocrinol (Oxf)*. 1998;48(1):89-97. <https://doi.org/10.1046/j.1365-2265.1998.00357.x>
 31. Nieman LK. Update on subclinical Cushing's syndrome. *Curr Opin Endocrinol Diabetes Obes*. 2015;22(3):180-184. <https://doi.org/10.1097/MED.0000000000000159>
 32. Elhassan YS, Alahdab F, Prete A, et al. Natural history of adrenal incidentalomas with and without mild autonomous cortisol excess: a systematic review and meta-analysis. *Ann Intern Med*. 2019;171(2):107-116. <https://doi.org/10.7326/M18-3630>
 33. Dekkers OM, Horvath-Puho E, Jorgensen JO, et al. Multisystem morbidity and mortality in Cushing's syndrome: a cohort study. *J Clin Endocrinol Metab*. 2013;98(6):2277-2284. <https://doi.org/10.1210/jc.2012-3582>
 34. Lacroix A, Feelders RA, Stratakis CA, Nieman LK. Cushing's syndrome. *Lancet*. 2015;386(9996):913-927. [https://doi.org/10.1016/S0140-6736\(14\)61375-1](https://doi.org/10.1016/S0140-6736(14)61375-1)
 35. Neychev V, Steinberg SM, Yang L, et al. Long-term outcome of bilateral laparoscopic adrenalectomy measured by disease-specific questionnaire in a unique group of patients with Cushing's syndrome. *Ann Surg Oncol*. 2015. <https://doi.org/10.1245/s10434-015-4605-1>
 36. Nieman LK, Biller BM, Findling JW, et al. Treatment of Cushing's syndrome: an endocrine society clinical practice guideline. *J Clin Endocrinol Metab*. 2015;100(8):2807-2831. <https://doi.org/10.1210/jc.2015-1818>
 37. Nieman LK. Cushing's syndrome: update on signs, symptoms and biochemical screening. *Eur J Endocrinol*. 2015;173(4):M33-M38. <https://doi.org/10.1530/EJE-15-0464>
 38. Lacroix A. Cardiometabolic morbidity of mild cortisol excess. *Ann Intern Med*. 2022;175(3):450-451. <https://doi.org/10.7326/M21-4526>
 39. Kjellbom A, Lindgren O, Puvaneswaralingam S, Londahl M, Olsen H. Association between mortality and levels of autonomous cortisol secretion by adrenal incidentalomas: a cohort study. *Ann Intern Med*. 2021;174(8):1041-1049. <https://doi.org/10.7326/M20-7946>
 40. Deutschbein T, Reimondo G, Di Dalmazi G, et al. Age-dependent and sex-dependent disparity in mortality in patients with adrenal incidentalomas and autonomous cortisol secretion: an international, retrospective, cohort study. *Lancet Diabetes Endocrinol*. 2022;10(7):499-508. [https://doi.org/10.1016/S2213-8587\(22\)00100-0](https://doi.org/10.1016/S2213-8587(22)00100-0)
 41. Caoili EM, Korobkin M, Francis IR, et al. Adrenal masses: characterization with combined unenhanced and delayed enhanced CT. *Radiology*. 2002;222(3):629-633. <https://doi.org/10.1148/radiol.2223010766>
 42. Blake MA, Kalra MK, Sweeney AT, et al. Distinguishing benign from malignant adrenal masses: multi-detector row CT protocol with 10-minute delay. *Radiology*. 2006;238(2):578-585. <https://doi.org/10.1148/radiol.2382041514>
 43. Ilias I, Sahdev A, Reznick RH, Grossman AB, Pacak K. The optimal imaging of adrenal tumours: a comparison of different methods. *Endocr Relat Cancer*. 2007;14(3):587-599. <https://doi.org/10.1677/ERC-07-0045>
 44. Hong AR, Kim JH, Park KS, et al. Optimal follow-up strategies for adrenal incidentalomas: reappraisal of the 2016 ESE-ENSAT guidelines in real clinical practice. *Eur J Endocrinol*. 2017;177(6):475-483. <https://doi.org/10.1530/EJE-17-0372>
 45. Mackie GC, Shulkin BL, Ribeiro RC, et al. Use of [18F]fluorodeoxyglucose positron emission tomography in evaluating locally recurrent and metastatic adrenocortical carcinoma. *J Clin Endocrinol Metab*. 2006;91(7):2665-2671. <https://doi.org/10.1210/jc.2005-2612>
 46. Groussin L, Bonardel G, Silvera S, et al. 18F-fluorodeoxyglucose Positron emission tomography for the diagnosis of adrenocortical tumors: a prospective study in 77 operated patients. *J Clin Endocrinol Metab*. 2009;94(5):1713-1722. <https://doi.org/10.1210/jc.2008-2302>
 47. Deandreis D, Leboulleux S, Caramella C, Schlumberger M, Baudin E. FDG PET in the management of patients with adrenal masses and adrenocortical carcinoma. *Horm Cancer*. 2011;2(6):354-362. <https://doi.org/10.1007/s12672-011-0091-5>
 48. Launay N, Silvera S, Tenenbaum F, et al. Value of 18-F-FDG PET/CT and CT in the diagnosis of indeterminate adrenal masses. *Int J Endocrinol*. 2015;2015:213875. <https://doi.org/10.1155/2015/213875>

49. Nakajo M, Jinguji M, Fukukura Y, *et al.* FDG-PET/CT and FLT-PET/CT for differentiating between lipid-poor benign and malignant adrenal tumours. *Eur Radiol.* 2015;25(12):3696-3705. <https://doi.org/10.1007/s00330-015-3787-z>
50. Delivanis DA, Bancos I, Atwell TD, *et al.* Diagnostic performance of unenhanced computed tomography and (18) F-fluorodeoxyglucose positron emission tomography in indeterminate adrenal tumours. *Clin Endocrinol (Oxf).* 2018;88(1):30-36. <https://doi.org/10.1111/cen.13448>
51. He X, Caoili EM, Avram AM, Miller BS, Else T. 18F-FDG-PET/CT evaluation of indeterminate adrenal masses in noncancer patients. *J Clin Endocrinol Metab.* 2021;106(5):1448-1459. <https://doi.org/10.1210/clinem/dgab005>
52. Salgues B, Guerin C, Amodru V, *et al.* Risk stratification of adrenal masses by [(18) F]FDG PET/CT: changing tactics. *Clin Endocrinol (Oxf).* 2021;94(2):133-140. <https://doi.org/10.1111/cen.14338>
53. McNicholas MM, Lee MJ, Mayo-Smith WW, Hahn PF, Boland GW, Mueller PR. An imaging algorithm for the differential diagnosis of adrenal adenomas and metastases. *AJR Am J Roentgenol.* 1995;165(6):1453-1459. <https://doi.org/10.2214/ajr.165.6.7484585>
54. Sahdev A, Reznick RH. Imaging evaluation of the non-functioning indeterminate adrenal mass. *Trends Endocrinol Metab.* 2004;15(6):271-276. <https://doi.org/10.1016/j.tem.2004.06.012>
55. Korobkin M, Giordano TJ, Brodeur FJ, *et al.* Adrenal adenomas: relationship between histologic lipid and CT and MR findings. *Radiology.* 1996;200(3):743-747. <https://doi.org/10.1148/radiology.200.3.8756925>
56. Korobkin M, Francis IR, Kloos RT, Dunnick NR. The incidental adrenal mass. *Radiol Clin North Am.* 1996;34(5):1037-1054. [https://doi.org/10.1016/S0033-8389\(22\)00684-4](https://doi.org/10.1016/S0033-8389(22)00684-4)
57. Haider MA, Ghai S, Jhaveri K, Lockwood G. Chemical shift MR imaging of hyperattenuating (>10 HU) adrenal masses: does it still have a role? *Radiology.* 2004;231(3):711-716. <https://doi.org/10.1148/radiol.2313030676>
58. Young WF Jr. Conventional imaging in adrenocortical carcinoma: update and perspectives. *Horm Cancer.* 2011;2(6):341-347. <https://doi.org/10.1007/s12672-011-0089-z>
59. Bharwani N, Rockall AG, Sahdev A, *et al.* Adrenocortical carcinoma: the range of appearances on CT and MRI. *AJR Am J Roentgenol.* 2011;196(6):W706-W714. <https://doi.org/10.2214/AJR.10.5540>
60. Becherer A, Vierhapper H, Potzi C, *et al.* FDG-PET in adrenocortical carcinoma. *Cancer Biother Radiopharm.* 2001;16:289-295.
61. Nieman LK, Biller BM, Findling JW, *et al.* The diagnosis of Cushing's syndrome: an endocrine society clinical practice guideline. *J Clin Endocrinol Metab.* 2008;93(5):1526-1540. <https://doi.org/10.1210/jc.2008-0125>
62. Lenders JW, Duh QY, Eisenhofer G, *et al.* Pheochromocytoma and paraganglioma: an endocrine society clinical practice guideline. *J Clin Endocrinol Metab.* 2014;99(6):1915-1942. <https://doi.org/10.1210/jc.2014-1498>
63. Funder JW, Carey RM, Mantero F, *et al.* The management of primary aldosteronism: case detection, diagnosis, and treatment: an endocrine society clinical practice guideline. *J Clin Endocrinol Metab.* 2016;101(5):1889-1916. <https://doi.org/10.1210/jc.2015-4061>
64. Fleseriu M, Auchus R, Bancos I, *et al.* Consensus on diagnosis and management of Cushing's disease: a guideline update. *Lancet Diabetes Endocrinol.* 2021;9(12):847-875. [https://doi.org/10.1016/S2213-8587\(21\)00235-7](https://doi.org/10.1016/S2213-8587(21)00235-7)
65. Fassnacht M, Arlt W, Bancos I, *et al.* Management of adrenal incidentalomas: European Society of Endocrinology clinical practice guideline in collaboration with the European Network for the Study of Adrenal Tumors. *Eur J Endocrinol.* 2016;175(2):G1-G34. <https://doi.org/10.1530/EJE-16-0467>
66. Bollerslev J, Rejnmark L, Marcocci C, *et al.* European Society of Endocrinology clinical guideline: treatment of chronic hypoparathyroidism in adults. *Eur J Endocrinol.* 2015;173(2):G1-G20. <https://doi.org/10.1530/EJE-15-0628>
67. Andrews JC, Schunemann HJ, Oxman AD, *et al.* GRADE guidelines: 15. Going from evidence to recommendation-determinants of a recommendation's direction and strength. *J Clin Epidemiol.* 2013;66(7):726-735. <https://doi.org/10.1016/j.jclinepi.2013.02.003>
68. Ferreira EV, Czepielewski MA, Faccin CS, Accordi MC, Furtado AP. [Prevalence of adrenal incidentaloma at computed tomography (chest and abdominal) in a general hospital in Brazil]. *Arq Bras Endocrinol Metabol.* 2005;49(5):769-775. <https://doi.org/10.1590/S0004-27302005000500017>
69. Pelsma I, Fassnacht M, Tsagarakis S, *et al.* Comorbidities in mild autonomous cortisol secretion and the effect of treatment: systematic review and meta-analysis. *Eur J Endocrinol* 2023 in press
70. Kahramangil B, Kose E, Remer EM, *et al.* A modern assessment of cancer risk in adrenal incidentalomas: analysis of 2219 patients. *Ann Surg.* 2022;275(1):e238-e244. <https://doi.org/10.1097/SLA.0000000000004048>
71. Angelelli G, Mancini ME, Moschetta M, Pedote P, Pignataro P, Scardapane A. MDCT In the differentiation of adrenal masses: comparison between different scan delays for the evaluation of intralesional washout. *ScientificWorldJournal.* 2013;2013:957680. <https://doi.org/10.1155/2013/957680>
72. Schloetelburg W, Ebert I, Petritsch B, *et al.* Adrenal wash-out CT: moderate diagnostic value in distinguishing benign from malignant adrenal masses. *Eur J Endocrinol.* 2021;186(2):183-193. <https://doi.org/10.1530/EJE-21-0650>
73. Marty M, Gaye D, Perez P, *et al.* Diagnostic accuracy of computed tomography to identify adenomas among adrenal incidentalomas in an endocrinological population. *Eur J Endocrinol.* 2018;178(5):439-446. <https://doi.org/10.1530/EJE-17-1056>
74. Vilar L, Freitas MdaC, Canadas V, *et al.* Adrenal incidentalomas: diagnostic evaluation and long-term follow-up. *Endocr Pract* 2008;14(3):269-278. <https://doi.org/10.4158/EP.ep.14.3.269>
75. Corwin MT, Badawy M, Caoili EM, *et al.* Incidental adrenal nodules in patients without known malignancy: prevalence of malignancy and utility of washout CT for characterization-a multiinstitutional study. *AJR Am J Roentgenol.* 2022;219(5):804-812. <https://doi.org/10.2214/AJR.22.27901>
76. Dinnes J, Bancos I, Ferrante di Ruffano L, *et al.* Management of endocrine disease: imaging for the diagnosis of malignancy in incidentally discovered adrenal masses: a systematic review and meta-analysis. *Eur J Endocrinol.* 2016;175(2):R51-R64. <https://doi.org/10.1530/EJE-16-0461>
77. Sandrasegaran K, Patel AA, Ramaswamy R, *et al.* Characterization of adrenal masses with diffusion-weighted imaging. *AJR Am J Roentgenol.* 2011;197(1):132-138. <https://doi.org/10.2214/AJR.10.4583>
78. Maurea S, Caraco C, Klain M, Mainolfi C, Salvatore M. Imaging characterization of non-hypersecreting adrenal masses. Comparison between MR and radionuclide techniques. *Q J Nucl Med Mol Imaging.* 2004;48:188-197.
79. Marin D, Dale BM, Bashir MR, *et al.* Effectiveness of a three-dimensional dual gradient echo two-point dixon technique for the characterization of adrenal lesions at 3 tesla. *Eur Radiol.* 2012;22(1):259-268. <https://doi.org/10.1007/s00330-011-2244-x>
80. Burt M, Heelan RT, Coit D, *et al.* Prospective evaluation of unilateral adrenal masses in patients with operable non-small-cell lung cancer. Impact of magnetic resonance imaging. *J Thorac Cardiovasc Surg.* 1994;107(2):584-588; discussion 588-589. [https://doi.org/10.1016/S0022-5223\(94\)70106-7](https://doi.org/10.1016/S0022-5223(94)70106-7)
81. Ream JM, Gaing B, Mussi TC, Rosenkrantz AB. Characterization of adrenal lesions at chemical-shift MRI: a direct intraindividual comparison of in- and opposed-phase imaging at 1.5T and 3T. *AJR Am J Roentgenol.* 2015;204(3):536-541. <https://doi.org/10.2214/AJR.14.12941>
82. Schwartz LH, Panicek DM, Koutcher JA, *et al.* Adrenal masses in patients with malignancy: prospective comparison of echo-planar,

- fast spin-echo, and chemical shift MR imaging. *Radiology*. 1995;197(2):421-425. <https://doi.org/10.1148/radiology.197.2.7480686>
83. Guerin C, Pattou F, Brunaud L, *et al.* Performance of 18F-FDG PET/CT in the characterization of adrenal masses in noncancer patients: a prospective study. *J Clin Endocrinol Metab*. 2017;102(7):2465-2472. <https://doi.org/10.1210/jc.2017-00254>
 84. Nunes ML, Rault A, Teynie J, *et al.* 18F-FDG PET for the identification of adrenocortical carcinomas among indeterminate adrenal tumors at computed tomography scanning. *World J Surg*. 2010;34(7):1506-1510. <https://doi.org/10.1007/s00268-010-0576-3>
 85. Tessonnier L, Sebag F, Palazzo FF, *et al.* Does 18F-FDG PET/CT add diagnostic accuracy in incidentally identified non-secreting adrenal tumours? *Eur J Nucl Med Mol Imaging*. 2008;35(11):2018-2025. <https://doi.org/10.1007/s00259-008-0849-3>
 86. Bancos I, Tamhane S, Shah M, *et al.* Diagnosis of endocrine disease: the diagnostic performance of adrenal biopsy: a systematic review and meta-analysis. *Eur J Endocrinol*. 2016;175(2):R65-R80. <https://doi.org/10.1530/EJE-16-0297>
 87. Delivanis DA, Erickson D, Atwell TD, *et al.* Procedural and clinical outcomes of percutaneous adrenal biopsy in a high-risk population for adrenal malignancy. *Clin Endocrinol (Oxf)*. 2016;85(5):710-716. <https://doi.org/10.1111/cen.13117>
 88. Zhang CD, Erickson D, Levy MJ, *et al.* Endoscopic ultrasound-guided fine-needle aspiration in the diagnosis of adrenal metastasis in a high-risk population. *Endocr Pract*. 2017;23(12):1402-1407. <https://doi.org/10.4158/EP-2017-0022>
 89. Novotny AG, Reynolds JP, Shah AA, *et al.* Fine-needle aspiration of adrenal lesions: a 20-year single institution experience with comparison of percutaneous and endoscopic ultrasound guided approaches. *Diagn Cytopathol*. 2019;47(10):986-992. <https://doi.org/10.1002/dc.24261>
 90. Martin-Cardona A, Fernandez-Esparrach G, Subtil JC, *et al.* EUS-guided tissue acquisition in the study of the adrenal glands: results of a nationwide multicenter study. *PLoS One*. 2019;14(6):e0216658. <https://doi.org/10.1371/journal.pone.0216658>
 91. McDermott E, Kilcoyne A, O'Shea A, Cahalane AM, McDermott S. The role of percutaneous CT-guided biopsy of an adrenal lesion in patients with known or suspected lung cancer. *Abdom Radiol (NY)*. 2021;46(3):1171-1178. <https://doi.org/10.1007/s00261-020-02743-9>
 92. Point du Jour KS, Alwalaie Y, Coleman A, Tadros T, Aneja R, Reid MD. Adrenal gland fine needle aspiration: a multi-institutional analysis of 139 cases. *J Am Soc Cytopathol*. 2021;10(2):168-174. <https://doi.org/10.1016/j.jasc.2020.08.004>
 93. Trabzonlu L, Jager L, Tabibi S, *et al.* Adrenal gland cytology reporting: a multi-institutional proposal for a standardized reporting system. *Cancer Cytopathol*. 2022;130(6):423-432. <https://doi.org/10.1002/cncy.22564>
 94. Orzechowski S, Gnass M, Wojtacha J, *et al.* Endosonography and endosonography guided needle aspiration for left adrenal gland assessment in lung cancer patients - 10 years' experience. *Adv Respir Med*. 2022;90(3):157-163. <https://doi.org/10.5603/ARM.a2022.0033>
 95. Arlt W, Biehl M, Taylor AE, *et al.* Urine steroid metabolomics as a biomarker tool for detecting malignancy in adrenal tumors. *J Clin Endocrinol Metab*. 2011;96(12):3775-3784. <https://doi.org/10.1210/jc.2011-1565>
 96. Kerkhofs TM, Kerstens MN, Kema IP, Willems TP, Haak HR. Diagnostic value of urinary steroid profiling in the evaluation of adrenal tumors. *Horm Cancer*. 2015;6(4):168-175. <https://doi.org/10.1007/s12672-015-0224-3>
 97. Taylor DR, Ghataore L, Couchman L, *et al.* A 13-steroid serum panel based on LC-MS/MS: use in detection of adrenocortical carcinoma. *Clin Chem*. 2017;63(12):1836-1846. <https://doi.org/10.1373/clinchem.2017.277624>
 98. Hines JM, Bancos I, Bancos C, *et al.* High-resolution, accurate-mass (HRAM) mass spectrometry urine steroid profiling in the diagnosis of adrenal disorders. *Clin Chem*. 2017;63(12):1824-1835. <https://doi.org/10.1373/clinchem.2017.271106>
 99. Schweitzer S, Kunz M, Kurlbaum M, *et al.* Plasma steroid metabolome profiling for the diagnosis of adrenocortical carcinoma. *Eur J Endocrinol*. 2019;180(2):117-125. <https://doi.org/10.1530/EJE-18-0782>
 100. Berke K, Constantinescu G, Masjkur J, *et al.* Plasma steroid profiling in patients with adrenal incidentaloma. *J Clin Endocrinol Metab*. 2022;107(3):e1181-e1192. <https://doi.org/10.1210/clinem/dgab751>
 101. Chiodini I, Guglielmi G, Battista C, *et al.* Spinal volumetric bone mineral density and vertebral fractures in female patients with adrenal incidentalomas: the effects of subclinical hypercortisolism and gonadal status. *J Clin Endocrinol Metab*. 2004;89(5):2237-2241. <https://doi.org/10.1210/jc.2003-031413>
 102. Chiodini I, Morelli V, Masserini B, *et al.* Bone mineral density, prevalence of vertebral fractures, and bone quality in patients with adrenal incidentalomas with and without subclinical hypercortisolism: an Italian multicenter study. *J Clin Endocrinol Metab*. 2009;94(9):3207-3214. <https://doi.org/10.1210/jc.2009-0468>
 103. Di Dalmazi G, Vicennati V, Rinaldi E, *et al.* Progressively increased patterns of subclinical cortisol hypersecretion in adrenal incidentalomas differently predict major metabolic and cardiovascular outcomes: a large cross-sectional study. *Eur J Endocrinol*. 2012;166(4):669-677. <https://doi.org/10.1530/EJE-11-1039>
 104. Eller-Vainicher C, Morelli V, Olivieri FM, *et al.* Bone quality, as measured by trabecular bone score in patients with adrenal incidentalomas with and without subclinical hypercortisolism. *J Bone Miner Res*. 2012;27(10):2223-2230. <https://doi.org/10.1002/jbmr.1648>
 105. Androulakis II, Kaltsas GA, Kollias GE, *et al.* Patients with apparently nonfunctioning adrenal incidentalomas may be at increased cardiovascular risk due to excessive cortisol secretion. *J Clin Endocrinol Metab*. 2014;99(8):2754-2762. <https://doi.org/10.1210/jc.2013-4064>
 106. Olsen H, Nordenstrom E, Bergenfelz A, *et al.* Subclinical hypercortisolism and CT appearance in adrenal incidentalomas: a multicenter study from Southern Sweden. *Endocrine*. 2012;42(1):164-173. <https://doi.org/10.1007/s12020-012-9622-2>
 107. Vassilatou E, Vryonidou A, Ioannidis D, Paschou SA, Panagou M, Tzavara I. Bilateral adrenal incidentalomas differ from unilateral adrenal incidentalomas in subclinical cortisol hypersecretion but not in potential clinical implications. *Eur J Endocrinol*. 2014;171(1):37-45. <https://doi.org/10.1530/EJE-13-0848>
 108. Abe I, Sugimoto K, Miyajima T, *et al.* Clinical investigation of adrenal incidentalomas in Japanese patients of the fukuoka region with updated diagnostic criteria for sub-clinical Cushing's syndrome. *Intern Med*. 2018;57(17):2467-2472. <https://doi.org/10.2169/internalmedicine.0550-17>
 109. Ahn SH, Kim JH, Cho YY, *et al.* The effects of cortisol and adrenal androgen on bone mass in asians with and without subclinical hypercortisolism. *Osteoporos Int*. 2019;30(5):1059-1069. <https://doi.org/10.1007/s00198-019-04871-5>
 110. Araujo-Castro M, Parra Ramirez P, Robles Lazaro C, *et al.* Accuracy of the dexamethasone suppression test for the prediction of autonomous cortisol secretion-related comorbidities in adrenal incidentalomas. *Hormones (Athens)*. 2021;20(4):735-744. <https://doi.org/10.1007/s42000-021-00308-z>
 111. Araujo-Castro M, Robles Lazaro C, Parra Ramirez P, *et al.* Maximum adenoma diameter, regardless of uni- or bilaterality, is a risk factor for autonomous cortisol secretion in adrenal incidentalomas. *J Endocrinol Invest*. 2021;44(11):2349-2357. <https://doi.org/10.1007/s40618-021-01539-y>
 112. Ceccato F, Barbot M, Albiger N, *et al.* Daily salivary cortisol and cortisone rhythm in patients with adrenal incidentaloma.

- Endocrine*. 2018;59(3):510-519. <https://doi.org/10.1007/s12020-017-1421-3>
113. Delivanis DA, Iniguez-Ariza NM, Zeb MH, *et al.* Impact of hypercortisolism on skeletal muscle mass and adipose tissue mass in patients with adrenal adenomas. *Clin Endocrinol (Oxf)*. 2018;88(2):209-216. <https://doi.org/10.1111/cen.13512>
 114. Delivanis DA, Hurtado Andrade MD, Cortes T, *et al.* Abnormal body composition in patients with adrenal adenomas. *Eur J Endocrinol*. 2021;185(5):653-662. <https://doi.org/10.1530/EJE-21-0458>
 115. Di Dalmazi G, Quinkler M, Deutschbein T, *et al.* Cortisol-related metabolic alterations assessed by mass spectrometry assay in patients with Cushing's syndrome. *Eur J Endocrinol*. 2017;177(2):227-237. <https://doi.org/10.1530/EJE-17-0109>
 116. Di Dalmazi G, Fanelli F, Zavatta G, *et al.* The steroid profile of adrenal incidentalomas: subtyping subjects with high cardiovascular risk. *J Clin Endocrinol Metab*. 2019;104(11):5519-5528. <https://doi.org/10.1210/jc.2019-00365>
 117. Di Dalmazi G, Vicennati V, Pizzi C, *et al.* Prevalence and incidence of atrial fibrillation in a large cohort of adrenal incidentalomas: a long-term study. *J Clin Endocrinol Metab*. 2020;105(8). <https://doi.org/10.1210/clinem/dgaa270>
 118. Falchetta P, Orsolini F, Benelli E, *et al.* Clinical features, risk of mass enlargement, and development of endocrine hyperfunction in patients with adrenal incidentalomas: a long-term follow-up study. *Endocrine*. 2021;71(1):178-188. <https://doi.org/10.1007/s12020-020-02476-1>
 119. Ishida A, Igarashi K, Ruike Y, *et al.* Association of urinary free cortisol with bone formation in patients with mild autonomous cortisol secretion. *Clin Endocrinol (Oxf)*. 2021;94(4):544-550. <https://doi.org/10.1111/cen.14385>
 120. Kong SH, Kim JH, Shin CS. Contralateral adrenal thinning as a distinctive feature of mild autonomous cortisol excess of the adrenal tumors. *Eur J Endocrinol*. 2020;183(3):325-333. <https://doi.org/10.1530/EJE-20-0301>
 121. Masserini B, Morelli V, Palmieri S, *et al.* Lipid abnormalities in patients with adrenal incidentalomas: role of subclinical hypercortisolism and impaired glucose metabolism. *J Endocrinol Invest*. 2015;38(6):623-628. <https://doi.org/10.1007/s40618-014-0232-0>
 122. Morelli V, Ghielmetti A, Caldiroli A, *et al.* Mental health in patients with adrenal incidentalomas: is there a relation with different degrees of cortisol secretion? *J Clin Endocrinol Metab*. 2021;106(1):e130-e139. <https://doi.org/10.1210/clinem/dgaa695>
 123. Morelli V, Scillitani A, Arosio M, Chiodini I. Follow-up of patients with adrenal incidentaloma, in accordance with the European society of endocrinology guidelines: could we be safe? *J Endocrinol Invest*. 2017;40(3):331-333. <https://doi.org/10.1007/s40618-016-0558-x>
 124. Sbardella E, Minnetti M, D'Aluisio D, *et al.* Cardiovascular features of possible autonomous cortisol secretion in patients with adrenal incidentalomas. *Eur J Endocrinol*. 2018;178(5):501-511. <https://doi.org/10.1530/EJE-17-0986>
 125. Singh S, Atkinson EJ, Achenbach SJ, LeBrasseur N, Bancos I. Frailty in patients with mild autonomous cortisol secretion is higher than in patients with nonfunctioning adrenal tumors. *J Clin Endocrinol Metab*. 2020;105(9):e3307-e3315. <https://doi.org/10.1210/clinem/dgaa410>
 126. Thompson LH, Ranstam J, Almquist M, Nordenstrom E, Bergenfelz A. Impact of adrenalectomy on morbidity in patients with non-functioning adrenal cortical tumours, mild hypercortisolism and Cushing's syndrome as assessed by national and quality registries. *World J Surg*. 2021;45(10):3099-3107. <https://doi.org/10.1007/s00268-021-06214-0>
 127. Kim BJ, Kwak MK, Ahn SH, Kim JS, Lee SH, Koh JM. The association of cortisol and adrenal androgen with trabecular bone score in patients with adrenal incidentaloma with and without autonomous cortisol secretion. *Osteoporos Int*. 2018;29(10):2299-2307. <https://doi.org/10.1007/s00198-018-4608-4>
 128. Moraes AB, Cavalari EMR, de Paula MP, *et al.* Evaluation of body composition using dual-energy X-ray absorptiometry in patients with non-functioning adrenal incidentalomas and an intermediate phenotype: is there an association with metabolic syndrome? *J Endocrinol Invest*. 2019;42(7):797-807. <https://doi.org/10.1007/s40618-018-0985-y>
 129. Sojat AS, Dunjic-Kostic B, Marina LV, *et al.* Depression: another cortisol-related comorbidity in patients with adrenal incidentalomas and (possible) autonomous cortisol secretion. *J Endocrinol Invest*. 2021;44(9):1935-1945. <https://doi.org/10.1007/s40618-021-01509-4>
 130. Debono M, Bradburn M, Bull M, Harrison B, Ross RJ, Newell-Price J. Cortisol as a marker for increased mortality in patients with incidental adrenocortical adenomas. *J Clin Endocrinol Metab*. 2014;99(12):4462-4470. <https://doi.org/10.1210/jc.2014-3007>
 131. Di Dalmazi G, Vicennati V, Garelli S, *et al.* Cardiovascular events and mortality in patients with adrenal incidentalomas that are either non-secreting or associated with intermediate phenotype or subclinical Cushing's Syndrome: a 15-year retrospective study. *Lancet Diabetes Endocrinol*. 2014;2(5):396-405. [https://doi.org/10.1016/S2213-8587\(13\)70211-0](https://doi.org/10.1016/S2213-8587(13)70211-0)
 132. Giordano R, Marinazzo E, Berardelli R, *et al.* Long-term morphological, hormonal, and clinical follow-up in a single unit on 118 patients with adrenal incidentalomas. *Eur J Endocrinol*. 2010;162(4):779-785. <https://doi.org/10.1530/EJE-09-0957>
 133. Morelli V, Eller-Vainicher C, Salcuni AS, *et al.* Risk of new vertebral fractures in patients with adrenal incidentaloma with and without subclinical hypercortisolism: a multicenter longitudinal study. *J Bone Miner Res*. 2011;26(8):1816-1821. <https://doi.org/10.1002/jbmr.398>
 134. Morelli V, Reimondo G, Giordano R, *et al.* Long-term follow-up in adrenal incidentalomas: an Italian multicenter study. *J Clin Endocrinol Metab*. 2014;99(3):827-834. <https://doi.org/10.1210/jc.2013-3527>
 135. Ceccato F, Antonelli G, Frigo AC, *et al.* First-line screening tests for Cushing's syndrome in patients with adrenal incidentaloma: the role of urinary free cortisol measured by LC-MS/MS. *J Endocrinol Invest*. 2017;40(7):753-760. <https://doi.org/10.1007/s40618-017-0644-8>
 136. Araujo-Castro M, Robles Lazaro C, Parra Ramirez P, Cuesta Hernandez M, Sampedro Nunez MA, Marazuela M. Cardiometabolic profile of non-functioning and autonomous cortisol-secreting adrenal incidentalomas. Is the cardiometabolic risk similar or are there differences? *Endocrine*. 2019;66(3):650-659. <https://doi.org/10.1007/s12020-019-02066-w>
 137. Li D, Kaur RJ, Zhang CD, *et al.* Risk of bone fractures after the diagnosis of adrenal adenomas: a population-based cohort study. *Eur J Endocrinol*. 2021;184(4):597-606. <https://doi.org/10.1530/EJE-20-1396>
 138. Papanastasiou L, Alexandraki KI, Androulakis II, *et al.* Concomitant alterations of metabolic parameters, cardiovascular risk factors and altered cortisol secretion in patients with adrenal incidentalomas during prolonged follow-up. *Clin Endocrinol (Oxf)*. 2017;86(4):488-498. <https://doi.org/10.1111/cen.13294>
 139. Patrova J, Kjellman M, Wahrenberg H, Falhammar H. Increased mortality in patients with adrenal incidentalomas and autonomous cortisol secretion: a 13-year retrospective study from one center. *Endocrine*. 2017;58(2):267-275. <https://doi.org/10.1007/s12020-017-1400-8>
 140. Petramala L, Olmati F, Concistre A, *et al.* Cardiovascular and metabolic risk factors in patients with subclinical cushing. *Endocrine*. 2020;70(1):150-163. <https://doi.org/10.1007/s12020-020-02297-2>
 141. Yener S, Baris M, Peker A, Demir O, Ozgen B, Secil M. Autonomous cortisol secretion in adrenal incidentalomas and increased visceral fat accumulation during follow-up. *Clin Endocrinol (Oxf)*. 2017;87(5):425-432. <https://doi.org/10.1111/cen.13408>

142. Zhang CD, Li D, Kaur RJ, *et al.* Cardiometabolic outcomes and mortality in patients with adrenal adenomas in a population-based setting. *J Clin Endocrinol Metab.* 2021;106(11):3320-3330. <https://doi.org/10.1210/clinem/dgab468>
143. Minnetti M, Hasenmajer V, Sbardella E, *et al.* Susceptibility and characteristics of infections in patients with glucocorticoid excess or insufficiency: the ICARO tool. *Eur J Endocrinol.* 2022;187(5):719-731. <https://doi.org/10.1530/EJE-22-0454>
144. Toniato A, Merante-Boschin I, Opocher G, Pelizzo MR, Schiavi F, Ballotta E. Surgical versus conservative management for subclinical Cushing syndrome in adrenal incidentalomas: a prospective randomized study. *Ann Surg.* 2009;249(3):388-391. <https://doi.org/10.1097/SLA.0b013e31819a47d2>
145. Morelli V, Frigerio S, Aresta C, *et al.* Adrenalectomy improves blood pressure and metabolic control in patients with possible autonomous cortisol secretion: results of a RCT. *Front Endocrinol (Lausanne).* 2022;13:898084. <https://doi.org/10.3389/fendo.2022.898084>
146. Chiodini I, Morelli V, Salcuni AS, *et al.* Beneficial metabolic effects of prompt surgical treatment in patients with an adrenal incidentaloma causing biochemical hypercortisolism. *J Clin Endocrinol Metab.* 2010;95(6):2736-2745. <https://doi.org/10.1210/jc.2009-2387>
147. Iacobone M, Citton M, Viel G, *et al.* Adrenalectomy may improve cardiovascular and metabolic impairment and ameliorate quality of life in patients with adrenal incidentalomas and subclinical Cushing's syndrome. *Surgery.* 2012;152(6):991-997. <https://doi.org/10.1016/j.surg.2012.08.054>
148. Perogamvros I, Vassiliadi DA, Karapanou O, Botoula E, Tzanela M, Tsagarakis S. Biochemical and clinical benefits of unilateral adrenalectomy in patients with subclinical hypercortisolism and bilateral adrenal incidentalomas. *Eur J Endocrinol.* 2015;173(6):719-725. <https://doi.org/10.1530/EJE-15-0566>
149. Petramala L, Cavallaro G, Galassi M, *et al.* Clinical benefits of unilateral adrenalectomy in patients with subclinical hypercortisolism due to adrenal incidentaloma: results from a single center. *High Blood Press Cardiovasc Prev.* 2017;24(1):69-75. <https://doi.org/10.1007/s40292-017-0182-7>
150. Salcuni AS, Morelli V, Eller Vainicher C, *et al.* Adrenalectomy reduces the risk of vertebral fractures in patients with monolateral adrenal incidentalomas and subclinical hypercortisolism. *Eur J Endocrinol.* 2016;174(3):261-269. <https://doi.org/10.1530/EJE-15-0977>
151. Tsuiki M, Tanabe A, Takagi S, Naruse M, Takano K. Cardiovascular risks and their long-term clinical outcome in patients with subclinical Cushing's syndrome. *Endocr J.* 2008;55(4):737-745. <https://doi.org/10.1507/endocrj.K07E-177>
152. Wang D, Ji ZG, Li HZ, Zhang YS. Adrenalectomy was recommended for patients with subclinical Cushing's syndrome due to adrenal incidentaloma. *Cancer Biomark.* 2018;21(2):367-372. <https://doi.org/10.3233/CBM-170531>
153. Araujo-Castro M, Minguez Ojeda C, Sanchez Ramirez MN, Gomez Dos Santos V, Pascual-Corrales E, Fernandez-Argueso M. Adrenalectomy improves blood pressure control in nonfunctioning adrenal incidentalomas and glycemic and lipid control in patients with autonomous cortisol secretion. *Endocrine.* 2022;78(1):142-150. <https://doi.org/10.1007/s12020-022-03120-w>
154. Brix D, Allolio B, Fenske W, *et al.* Laparoscopic versus open adrenalectomy for adrenocortical carcinoma: surgical and oncologic outcome in 152 patients. *Eur Urol.* 2010;58(4):609-615. <https://doi.org/10.1016/j.eururo.2010.06.024>
155. Cooper AB, Habra MA, Grubbs EG, *et al.* Does laparoscopic adrenalectomy jeopardize oncologic outcomes for patients with adrenocortical carcinoma? *Surg Endosc.* 2013;27(11):4026-4032. <https://doi.org/10.1007/s00464-013-3034-0>
156. Donatini G, Caiazzo R, Do CC, *et al.* Long-term survival after adrenalectomy for stage I/II adrenocortical carcinoma (ACC): a retrospective comparative cohort study of laparoscopic versus open approach. *Ann Surg Oncol.* 2014;21(1):284-291. <https://doi.org/10.1245/s10434-013-3164-6>
157. Fossa A, Rosok BI, Kazaryan AM, *et al.* Laparoscopic versus open surgery in stage I-III adrenocortical carcinoma—a retrospective comparison of 32 patients. *Acta Oncol.* 2013;52(8):1771-1777. <https://doi.org/10.3109/0284186X.2013.765065>
158. Lombardi CP, Raffaelli M, De CC, *et al.* Open versus endoscopic adrenalectomy in the treatment of localized (stage I/II) adrenocortical carcinoma: results of a multiinstitutional Italian survey. *Surgery.* 2012;152(6):1158-1164. <https://doi.org/10.1016/j.surg.2012.08.014>
159. Miller BS, Ammori JB, Gauger PG, Broome JT, Hammer GD, Doherty GM. Laparoscopic resection is inappropriate in patients with known or suspected adrenocortical carcinoma. *World J Surg.* 2010;34(6):1380-1385. <https://doi.org/10.1007/s00268-010-0532-2>
160. Miller BS, Gauger PG, Hammer GD, Doherty GM. Resection of adrenocortical carcinoma is less complete and local recurrence occurs sooner and more often after laparoscopic adrenalectomy than after open adrenalectomy. *Surgery.* 2012;152(6):1150-1157. <https://doi.org/10.1016/j.surg.2012.08.024>
161. Mir MC, Klink JC, Guillotreau J, *et al.* Comparative outcomes of laparoscopic and open adrenalectomy for adrenocortical carcinoma: single, high-volume center experience. *Ann Surg Oncol.* 2013;20(5):1456-1461. <https://doi.org/10.1245/s10434-012-2760-1>
162. Porpiglia F, Fiori C, Daffara F, *et al.* Retrospective evaluation of the outcome of open versus laparoscopic adrenalectomy for stage I and II adrenocortical cancer. *Eur Urol.* 2010;57(5):873-878. <https://doi.org/10.1016/j.eururo.2010.01.036>
163. Calcaterra NA, Hsiung-Wang C, Suss NR, Winchester DJ, Moo-Young TA, Prinz RA. Minimally invasive adrenalectomy for adrenocortical carcinoma: five-year trends and predictors of conversion. *World J Surg.* 2018;42(2):473-481. <https://doi.org/10.1007/s00268-017-4290-2>
164. Hue JJ, Ahorukomeye P, Bingmer K, *et al.* A comparison of robotic and laparoscopic minimally invasive adrenalectomy for adrenal malignancies. *Surg Endosc.* 2022;36(7):5374-5381. <https://doi.org/10.1007/s00464-021-08827-x>
165. Kastelan D, Knezevic N, Zibar Tomsic K, *et al.* Open vs laparoscopic adrenalectomy for localized adrenocortical carcinoma. *Clin Endocrinol (Oxf).* 2020;93(4):404-408. <https://doi.org/10.1111/cen.14251>
166. Maurice MJ, Bream MJ, Kim SP, Abouassaly R. Surgical quality of minimally invasive adrenalectomy for adrenocortical carcinoma: a contemporary analysis using the national cancer database. *BJU Int.* 2017;119(3):436-443. <https://doi.org/10.1111/bju.13618>
167. Wu K, Liu Z, Liang J, *et al.* Laparoscopic versus open adrenalectomy for localized (stage 1/2) adrenocortical carcinoma: experience at a single, high-volume center. *Surgery.* 2018;164(6):1325-1329. <https://doi.org/10.1016/j.surg.2018.07.026>
168. Cawood TJ, Hunt PJ, O'Shea D, Cole D, Soule S. Recommended evaluation of adrenal incidentalomas is costly, has high false-positive rates and confers a risk of fatal cancer that is similar to the risk of the adrenal lesion becoming malignant; time for a rethink? *Eur J Endocrinol.* 2009;161(4):513-527. <https://doi.org/10.1530/EJE-09-0234>
169. Cho YY, Suh S, Joung JY, *et al.* Clinical characteristics and follow-up of Korean patients with adrenal incidentalomas. *Korean J Intern Med.* 2013;28(5):557-564. <https://doi.org/10.3904/kjim.2013.28.5.557>
170. Comlekci A, Yener S, Ertilav S, *et al.* Adrenal incidentaloma, clinical, metabolic, follow-up aspects: single centre experience. *Endocrine.* 2010;37(1):40-46. <https://doi.org/10.1007/s12020-009-9260-5>
171. Debono M, Prema A, Hughes TJ, Bull M, Ross RJ, Newell-Price J. Visceral fat accumulation and postdexamethasone serum cortisol levels in patients with adrenal incidentaloma. *J Clin Endocrinol*

- Metab.* 2013;98(6):2383-2391. <https://doi.org/10.1210/jc.2012-4276>
172. Kim HY, Kim SG, Lee KW, *et al.* Clinical study of adrenal incidentaloma in Korea. *Korean J Intern Med.* 2005;20(4):303-309. <https://doi.org/10.3904/kjim.2005.20.4.303>
 173. Muth A, Hammarstedt L, Hellstrom M, Sigurjonsdottir HA, Almqvist E, Wangberg B, Sweden ASGoW. Cohort study of patients with adrenal lesions discovered incidentally. *Br J Surg.* 2011;98(10):1383-1391. <https://doi.org/10.1002/bjs.7566>
 174. Muth A, Taft C, Hammarstedt L, Bjorneld L, Hellstrom M, Wangberg B. Patient-reported impacts of a conservative management programme for the clinically inapparent adrenal mass. *Endocrine.* 2013;44(1):228-236. <https://doi.org/10.1007/s12020-012-9856-z>
 175. Song JH, Chaudhry FS, Mayo-Smith WW. The incidental adrenal mass on CT: prevalence of adrenal disease in 1,049 consecutive adrenal masses in patients with no known malignancy. *AJR Am J Roentgenol.* 2008;190(5):1163-1168. <https://doi.org/10.2214/AJR.07.2799>
 176. Vassilatou E, Vryonidou A, Michalopoulou S, *et al.* Hormonal activity of adrenal incidentalomas: results from a long-term follow-up study. *Clin Endocrinol (Oxf).* 2009;70(5):674-679. <https://doi.org/10.1111/j.1365-2265.2008.03492.x>
 177. Yener S, Ertilav S, Secil M, *et al.* Natural course of benign adrenal incidentalomas in subjects with extra-adrenal malignancy. *Endocrine.* 2009;36(1):135-140. <https://doi.org/10.1007/s12020-009-9191-1>
 178. Araujo-Castro M, Parra Ramirez P, Robles Lazaro C, *et al.* Predictors of tumour growth and autonomous cortisol secretion development during follow-up in non-functioning adrenal incidentalomas. *J Clin Med.* 2021;10(23):5509.
 179. Ceccato F, Tizianel I, Voltan G, *et al.* Attenuation value in adrenal incidentalomas: a longitudinal study. *Front Endocrinol (Lausanne).* 2021;12:794197. <https://doi.org/10.3389/fendo.2021.794197>
 180. Collienne M, Timmesfeld N, Bergmann SR, Goebel J, Kann PH. Adrenal incidentaloma and subclinical Cushing's syndrome: a longitudinal follow-up study by endoscopic ultrasound. *Ultraschall Med.* 2017;38(04):411-419. <https://doi.org/10.1055/s-0041-107996>
 181. Corwin MT, Chalfant JS, Loehfelm TW, Fananapazir G, Lamba R, Mayo-Smith WW. Incidentally detected bilateral adrenal nodules in patients without cancer: is further workup necessary? *AJR Am J Roentgenol.* 2018;210(4):780-784. <https://doi.org/10.2214/AJR.17.18543>
 182. Goh Z, Phillips I, Hunt PJ, Soule S, Cawood TJ. Three-year follow up of adrenal incidentalomas in a New Zealand centre. *Intern Med J.* 2020;50(3):350-356. <https://doi.org/10.1111/imj.14332>
 183. Kastelan D, Kraljevic I, Dusek T, *et al.* The clinical course of patients with adrenal incidentaloma: is it time to reconsider the current recommendations? *Eur J Endocrinol.* 2015;173(2):275-282. <https://doi.org/10.1530/EJE-15-0199>
 184. Li T, Li W, Fang X, Lv Q, Song Y, Shi Y. Comprehensive analysis on 559 cases of adrenal incidentalomas in the elderly Chinese. *Aging Med (Milton).* 2018;1(1):35-38. <https://doi.org/10.1002/agm2.12006>
 185. Schalin-Jantti C, Raade M, Hamalainen E, Sane T. A 5-year prospective follow-up study of lipid-rich adrenal incidentalomas: no tumor growth or development of hormonal hypersecretion. *Endocrinol Metab (Seoul).* 2015;30(4):481-487. <https://doi.org/10.3803/EnM.2015.30.4.481>
 186. Yeomans H, Calissendorff J, Volpe C, Falhammar H, Mannheimer B. Limited value of long-term biochemical follow-up in patients with adrenal incidentalomas-a retrospective cohort study. *BMC Endocr Disord.* 2015;15(1):6. <https://doi.org/10.1186/s12902-015-0001-x>
 187. Vasilev V, Matrozova J, Elenkova A, Zacharieva S. Clinical characteristics and follow-up of incidentally found adrenal tumours - results from a single tertiary centre. *Cent Eur J Med.* 2014;9:292-301.
 188. Anagnostis P, Efstathiadou Z, Polyzos SA, *et al.* Long term follow-up of patients with adrenal incidentalomas—a single center experience and review of the literature. *Exp Clin Endocrinol Diabetes.* 2010;118(9):610-616. <https://doi.org/10.1055/s-0029-1237704>
 189. Tsvetov G, Shimon I, Benbassat C. Adrenal incidentaloma: clinical characteristics and comparison between patients with and without extraadrenal malignancy. *J Endocrinol Invest.* 2007;30(8):647-652. <https://doi.org/10.1007/BF03347444>
 190. Yilmaz N, Avsar E, Tazegul G, Sari R, Altunbas H, Balci MK. Clinical characteristics and follow-up results of adrenal incidentaloma. *Exp Clin Endocrinol Diabetes.* 2021;129(5):349-356. <https://doi.org/10.1055/a-1079-4915>
 191. Giordano TJ, Berney D, de Krijger RR, *et al.* Data set for reporting of carcinoma of the adrenal cortex: explanations and recommendations of the guidelines from the international collaboration on cancer reporting. *Hum Pathol.* 2021;110:50-61. <https://doi.org/10.1016/j.humpath.2020.10.001>
 192. Mihai R, Donatini G, Vidal O, Brunaud L. Volume-outcome correlation in adrenal surgery—an ESES consensus statement. *Langenbecks Arch Surg.* 2019;404(7):795-806. <https://doi.org/10.1007/s00423-019-01827-5>
 193. Savitz A, Fong B, Hochberg A, *et al.* Endocrine tumor board: ten years' experience of a multidisciplinary clinical working conference. *Perm J.* 2020;24(4):19.140. <https://doi.org/10.7812/TPP/19.140>
 194. Stone BV, Tallman JE, Moses KA. Disparate practice patterns and survival outcomes: the impact of centralization of cancer care for adrenocortical carcinoma in the United States. *J Urol.* 2021;206(4):866-872. <https://doi.org/10.1097/JU.0000000000001871>
 195. Zhang J, Yang J, Libianto R, *et al.* Impact of dedicated multidisciplinary service on patient selection and outcomes for surgical treatment of primary aldosteronism. *Surgery.* 2022;172(6):1682-1688. <https://doi.org/10.1016/j.surg.2022.08.010>
 196. Rodacki K, Ramalho M, Dale BM, *et al.* Combined chemical shift imaging with early dynamic serial gadolinium-enhanced MRI in the characterization of adrenal lesions. *AJR Am J Roentgenol.* 2014;203(1):99-106. <https://doi.org/10.2214/AJR.13.11731>
 197. Seo JM, Park BK, Park SY, Kim CK. Characterization of lipid-poor adrenal adenoma: chemical-shift MRI and washout CT. *AJR Am J Roentgenol.* 2014;202(5):1043-1050. <https://doi.org/10.2214/AJR.13.11389>
 198. Taffel MT, Petrocelli RD, Rigau D, *et al.* Prevalence of malignancy in adrenal nodules with heterogeneous microscopic fat on chemical-shift MRI: a multiinstitutional study. *AJR Am J Roentgenol.* 2023;220(1):86-94. <https://doi.org/10.2214/AJR.22.27976>
 199. Karam M, Novak L, Cyriac J, Ali A, Nazeer T, Nugent F. Role of fluorine-18 fluoro-deoxyglucose positron emission tomography scan in the evaluation and follow-up of patients with low-grade lymphomas. *Cancer.* 2006;107(1):175-183. <https://doi.org/10.1002/cncr.21967>
 200. Tsukamoto N, Kojima M, Hasegawa M, *et al.* The usefulness of (18)F-fluorodeoxyglucose positron emission tomography ((18)F-FDG-PET) and a comparison of (18)F-FDG-pet with (67)gallium scintigraphy in the evaluation of lymphoma: relation to histologic subtypes based on the world health organization classification. *Cancer.* 2007;110:652-659.
 201. Zukotynski K, Lewis A, O'Regan K, *et al.* PET/CT and renal pathology: a blind spot for radiologists? Part 1, primary pathology. *AJR Am J Roentgenol.* 2012;199(2):W163-W167. <https://doi.org/10.2214/AJR.11.7790>
 202. Ansquer C, Scigliano S, Mirallie E, *et al.* 18F-FDG PET/CT in the characterization and surgical decision concerning adrenal masses: a prospective multicentre evaluation. *Eur J Nucl Med Mol Imaging.* 2010;37(9):1669-1678. <https://doi.org/10.1007/s00259-010-1471-8>

203. Libe R, Pais A, Violon F, *et al.* Positive correlation between 18F-FDG uptake and tumor-proliferating antigen Ki-67 expression in adrenocortical carcinomas. *Clin Nucl Med.* 2023;48:381-386. <https://doi.org/10.1097/RLU.00000000000004593>
204. Timmers HJ, Chen CC, Carrasquillo JA, *et al.* Comparison of 18F-fluoro-L-DOPA, 18F-fluoro-deoxyglucose, and 18F-fluorodopamine PET and 123I-MIBG scintigraphy in the localization of pheochromocytoma and paraganglioma. *J Clin Endocrinol Metab.* 2009;94(12):4757-4767. <https://doi.org/10.1210/jc.2009-1248>
205. Alencar GA, Fragoso MC, Yamaga LY, Lerario AM, Mendonca BB. (18)F-FDG-PET/CT imaging of ACTH-independent macronodular adrenocortical hyperplasia (AIMAH) demonstrating increased (18)F-FDG uptake. *J Clin Endocrinol Metab.* 2011;96(11):3300-3301. <https://doi.org/10.1210/jc.2011-1397>
206. Herndon J, Nadeau AM, Davidge-Pitts CJ, Young WF, Bancos I. Primary adrenal insufficiency due to bilateral infiltrative disease. *Endocrine.* 2018;62(3):721-728. <https://doi.org/10.1007/s12020-018-1737-7>
207. Patel S, Jinjuvadia R, Devara A, *et al.* Performance characteristics of EUS-FNA biopsy for adrenal lesions: a meta-analysis. *Endosc Ultrasound.* 2019;8(3):180-187. https://doi.org/10.4103/eus.eus_42_18
208. Naffouje SA, Sabesan A, Hallanger-Johnson J, Kirtane K, Gonzalez RJ, Mullinax J. Adrenal biopsy, as a diagnostic method, is associated with decreased overall survival in patients with T1/T2 adrenocortical carcinoma: a propensity score-matched analysis. *J Surg Oncol.* 2021;124(8):1261-1271. <https://doi.org/10.1002/jso.26639>
209. Berruti A, Baudin E, Gelderblom H, *et al.* Adrenal cancer: ESMO clinical practice guidelines for diagnosis, treatment and follow-up. *Ann Oncol.* 2012;23(Suppl 7):vii131-vii138. <https://doi.org/10.1093/annonc/mds231>
210. Fassnacht M, Kroiss M, Allolio B. Update in adrenocortical carcinoma. *J Clin Endocrinol Metab.* 2013;98(12):4551-4564. <https://doi.org/10.1210/jc.2013-3020>
211. Libe R, Fratticci A, Bertherat J. Adrenocortical cancer: pathophysiology and clinical management. *Endocr Relat Cancer.* 2007;14(1):13-28. <https://doi.org/10.1677/erc.1.01130>
212. Else T, Kim AC, Sabolch A, *et al.* Adrenocortical carcinoma. *Endocr Rev.* 2014;35(2):282-326. <https://doi.org/10.1210/er.2013-1029>
213. Vogg N, Muller T, Floren A, *et al.* Simplified urinary steroid profiling by LC-MS as diagnostic tool for malignancy in adrenocortical tumors. *Clin Chim Acta.* 2023;543:117301. <https://doi.org/10.1016/j.cca.2023.117301>
214. Fassnacht M, Allolio B. Clinical management of adrenocortical carcinoma. *Best Pract Res Clin Endocrinol Metab.* 2009;23(2):273-289. <https://doi.org/10.1016/j.beem.2008.10.008>
215. Fassnacht M, Kenn W, Allolio B. Adrenal tumors: how to establish malignancy? *J Endocrinol Invest.* 2004;27(4):387-399. <https://doi.org/10.1007/BF03351068>
216. Denny MC, Annamalai AK, Prankerd-Smith O, *et al.* Low DHEAS: a sensitive and specific test for the detection of subclinical hypercortisolism in adrenal incidentalomas. *J Clin Endocrinol Metab.* 2017;102:786-792.
217. Liu MS, Lou Y, Chen H, *et al.* Performance of DHEAS as a screening test for autonomous cortisol secretion in adrenal incidentalomas: a prospective study. *J Clin Endocrinol Metab.* 2022;107(5):e1789-e1796. <https://doi.org/10.1210/clinem/dgac072>
218. Carafone LE, Zhang CD, Li D, *et al.* Diagnostic accuracy of dehydroepiandrosterone sulfate and corticotropin in autonomous cortisol secretion. *Biomedicine.* 2021;9(7):741. <https://doi.org/10.3390/biomedicine9070741>
219. Puvaneswaralingam S, Kjellbom A, Lindgren O, Londahl M, Olsen H. ACTH Following overnight dexamethasone suppression can be used in the verification of autonomous cortisol secretion in patients with adrenal incidentalomas. *Clin Endocrinol (Oxf).* 2021;94(2):168-175. <https://doi.org/10.1111/cen.14357>
220. Reimondo G, Allasino B, Bovio S, *et al.* Pros and cons of dexamethasone suppression test for screening of subclinical Cushing's syndrome in patients with adrenal incidentalomas. *J Endocrinol Invest.* 2011;34(1):e1-e5. <https://doi.org/10.1007/BF03346701>
221. Elamin MB, Murad MH, Mullan R, *et al.* Accuracy of diagnostic tests for Cushing's syndrome: a systematic review and meta-analysis. *J Clin Endocrinol Metab.* 2008;93(5):1553-1562. <https://doi.org/10.1210/jc.2008-0139>
222. Ueland GA, Methlie P, Kellmann R, *et al.* Simultaneous assay of cortisol and dexamethasone improved diagnostic accuracy of the dexamethasone suppression test. *Eur J Endocrinol.* 2017;176(6):705-713. <https://doi.org/10.1530/EJE-17-0078>
223. Vogg N, Kurlbaum M, Deutschbein T, Grasl B, Fassnacht M, Kroiss M. Method-specific cortisol and dexamethasone thresholds increase clinical specificity of the dexamethasone suppression test for Cushing syndrome. *Clin Chem.* 2021;67(7):998-1007. <https://doi.org/10.1093/clinchem/hvab056>
224. Genere N, Kaur RJ, Athimulam S, *et al.* Interpretation of abnormal dexamethasone suppression test is enhanced with use of synchronous free cortisol assessment. *J Clin Endocrinol Metab.* 2022;107(3):e1221-e1230. <https://doi.org/10.1210/clinem/dgab724>
225. Terzolo M, Bovio S, Reimondo G, *et al.* Subclinical Cushing's syndrome in adrenal incidentalomas. *Endocrinol Metab Clin North Am.* 2005;34(2):423-439, x. <https://doi.org/10.1016/j.ecl.2005.01.008>
226. Tauchmanova L, Rossi R, Biondi B, *et al.* Patients with subclinical Cushing's syndrome due to adrenal adenoma have increased cardiovascular risk. *J Clin Endocrinol Metab.* 2002;87(11):4872-4878. <https://doi.org/10.1210/jc.2001-011766>
227. Emral R, Uysal AR, Asik M, *et al.* Prevalence of subclinical Cushing's syndrome in 70 patients with adrenal incidentaloma: clinical, biochemical and surgical outcomes. *Endocr J.* 2003;50(4):399-408. <https://doi.org/10.1507/endocrj.50.399>
228. Reincke M, Fassnacht M, Vath S, Mora P, Allolio B. Adrenal incidentalomas: a manifestation of the metabolic syndrome? *Endocr Res.* 1996;22(4):757-761. <https://doi.org/10.1080/07435809609043773>
229. Bernini G, Moretti A, Iacconi P, *et al.* Anthropometric, haemodynamic, humoral and hormonal evaluation in patients with incidental adrenocortical adenomas before and after surgery. *Eur J Endocrinol.* 2003;148:213-219. <https://doi.org/10.1530/eje.0.1480213>
230. Fernandez-Real JM, Engel WR, Simo R, Salinas I, Webb SM. Study of glucose tolerance in consecutive patients harbouring incidental adrenal tumours. Study group of incidental adrenal adenoma. *Clin Endocrinol (Oxf).* 1998;49(1):53-61. <https://doi.org/10.1046/j.1365-2265.1998.00437.x>
231. Morelli V, Masserini B, Salcuni AS, *et al.* Subclinical hypercortisolism: correlation between biochemical diagnostic criteria and clinical aspects. *Clin Endocrinol (Oxf).* 2010;73:161-166.
232. Rossi R, Tauchmanova L, Luciano A, *et al.* Subclinical Cushing's syndrome in patients with adrenal incidentaloma: clinical and biochemical features. *J Clin Endocrinol Metab.* 2000;85:1440-1448.
233. Hadjidakis D, Tsagarakis S, Roboti C, *et al.* Does subclinical hypercortisolism adversely affect the bone mineral density of patients with adrenal incidentalomas? *Clin Endocrinol (Oxf).* 2003;58(1):72-77. <https://doi.org/10.1046/j.1365-2265.2003.01676.x>
234. Vinolas H, Grouthier V, Mehsen-Cetre N, *et al.* Assessment of vertebral microarchitecture in overt and mild Cushing's syndrome using trabecular bone score. *Clin Endocrinol (Oxf).* 2018;89(2):148-154. <https://doi.org/10.1111/cen.13743>
235. Hardy RS, Zhou H, Seibel MJ, Cooper MS. Glucocorticoids and bone: consequences of endogenous and exogenous excess and replacement therapy. *Endocr Rev.* 2018;39(5):519-548. <https://doi.org/10.1210/er.2018-00097>
236. Moraes AB, de Paula MP, de Paula Paranhos-Neto F, *et al.* Bone evaluation by high-resolution peripheral quantitative computed

- tomography in patients with adrenal incidentaloma. *J Clin Endocrinol Metab.* 2020;105(8):dgaa263. <https://doi.org/10.1210/clinem/dgaa263>
237. Kjellbom A, Lindgren O, Danielsson M, Olsen H, Londahl M. Mortality not increased in patients with non-functional adrenal adenomas: a matched cohort study. *J Clin Endocrinol Metab.* 2023. <https://doi.org/10.1210/clinem/dgad074>
 238. Buitenwerf E, Korteweg T, Visser A, *et al.* Unenhanced CT imaging is highly sensitive to exclude pheochromocytoma: a multicenter study. *Eur J Endocrinol.* 2018;178(5):431-437. <https://doi.org/10.1530/EJE-18-0006>
 239. Canu L, Van Hemert JAW, Kerstens MN, *et al.* CT characteristics of pheochromocytoma: relevance for the evaluation of adrenal incidentaloma. *J Clin Endocrinol Metab.* 2019;104(2):312-318. <https://doi.org/10.1210/jc.2018-01532>
 240. Mulatero P, Monticone S, Deinum J, *et al.* Genetics, prevalence, screening and confirmation of primary aldosteronism: a position statement and consensus of the working group on endocrine hypertension of the European society of hypertension. *J Hypertens.* 2020;38(10):1919-1928. <https://doi.org/10.1097/HJH.0000000000002510>
 241. Mulatero P, Sechi LA, Williams TA, *et al.* Subtype diagnosis, treatment, complications and outcomes of primary aldosteronism and future direction of research: a position statement and consensus of the working group on endocrine hypertension of the European Society of Hypertension. *J Hypertens.* 2020;38(10):1929-1936. <https://doi.org/10.1097/HJH.0000000000002520>
 242. Reincke M, Bancos I, Mulatero P, Scholl UI, Stowasser M, Williams TA. Diagnosis and treatment of primary aldosteronism. *Lancet Diabetes Endocrinol.* 2021;9(12):876-892. [https://doi.org/10.1016/S2213-8587\(21\)00210-2](https://doi.org/10.1016/S2213-8587(21)00210-2)
 243. Mulatero P, Bertello C, Veglio F, Monticone S. Approach to the patient on antihypertensive therapy: screen for primary aldosteronism. *J Clin Endocrinol Metab.* 2022;107:3175-3181. <https://doi.org/10.1210/clinem/dgac460>
 244. Vaidya A, Hundemer GL, Nanba K, Parksook WW, Brown JM. Primary aldosteronism: state-of-the-art review. *Am J Hypertens.* 2022;35:967-988. <https://doi.org/10.1093/ajh/hpac079>
 245. Park HS, Roman SA, Sosa JA. Outcomes from 3144 adrenalectomies in the United States: which matters more, surgeon volume or specialty? *Arch Surg.* 2009;144(11):1060-1067. <https://doi.org/10.1001/archsurg.2009.191>
 246. Kerkhofs TM, Verhoeven RH, Bonjer HJ, *et al.* Surgery for adrenocortical carcinoma in The Netherlands: analysis of the national cancer registry data. *Eur J Endocrinol.* 2013;169(1):83-89. <https://doi.org/10.1530/EJE-13-0142>
 247. Lombardi CP, Raffaelli M, Boniardi M, *et al.* Adrenocortical carcinoma: effect of hospital volume on patient outcome. *Langenbecks Arch Surg.* 2012;397(2):201-207. <https://doi.org/10.1007/s00423-011-0866-8>
 248. Anderson KL Jr., Thomas SM, Adam MA, *et al.* Each procedure matters: threshold for surgeon volume to minimize complications and decrease cost associated with adrenalectomy. *Surgery.* 2018;163(1):157-164. <https://doi.org/10.1016/j.surg.2017.04.028>
 249. Rahbari R, Alavi M, Alvarez JF, *et al.* Volume matters: longitudinal retrospective cohort study of outcomes following consultation and standardization of adrenal surgery. *Ann Surg Oncol.* 2021;28(13):8849-8860. <https://doi.org/10.1245/s10434-021-10297-3>
 250. Hue JJ, Bingmer K, Zhao H, *et al.* Reassessing the impact of tumor size on operative approach in adrenocortical carcinoma. *J Surg Oncol.* 2021;123(5):1238-1245. <https://doi.org/10.1002/jso.26418>
 251. Reibetanz J, Jurowich C, Erdogan I, *et al.* Impact of lymphadenectomy on the oncologic outcome of patients with adrenocortical carcinoma. *Ann Surg.* 2012;255(2):363-369. <https://doi.org/10.1097/SLA.0b013e3182367ac3>
 252. Tseng J, DiPeri T, Chen Y, *et al.* Adrenocortical carcinoma: the value of lymphadenectomy. *Ann Surg Oncol.* 2022;29(3):1965-1970. <https://doi.org/10.1245/s10434-021-11051-5>
 253. Hendricks A, Muller S, Fassnacht M, *et al.* Impact of lymphadenectomy on the oncologic outcome of patients with adrenocortical carcinoma—a systematic review and meta-analysis. *Cancers (Basel).* 2022;14(2):291.
 254. Morelli L, Tartaglia D, Bronzoni J, *et al.* Robotic assisted versus pure laparoscopic surgery of the adrenal glands: a case-control study comparing surgical techniques. *Langenbecks Arch Surg.* 2016;401(7):999-1006. <https://doi.org/10.1007/s00423-016-1494-0>
 255. Vatansever S, Nordenstrom E, Raffaelli M, Brunaud L, Makay O. Robot-assisted versus conventional laparoscopic adrenalectomy: results from the EUROCRINE surgical registry. *Surgery.* 2022;171(5):1224-1230. <https://doi.org/10.1016/j.surg.2021.12.003>
 256. Gaujoux S, Mihai R. European Society of Endocrine Surgeons (ESES) and European Network for the Study of Adrenal Tumours (ENSAT) recommendations for the surgical management of adrenocortical carcinoma. *Br J Surg.* 2017;104(4):358-376. <https://doi.org/10.1002/bjs.10414>
 257. Fassnacht M, Dekkers OM, Else T, *et al.* European Society of Endocrinology clinical practice guidelines on the management of adrenocortical carcinoma in adults, in collaboration with the European Network for the Study of Adrenal Tumours. *Eur J Endocrinol.* 2018;179(4):G1-G46. <https://doi.org/10.1530/EJE-18-0608>
 258. Fassnacht M, Assie G, Baudin E, *et al.* Adrenocortical carcinomas and malignant pheochromocytomas: ESMO-EURACAN clinical practice guidelines for diagnosis, treatment and follow-up. *Ann Oncol.* 2020;31(11):1476-1490. <https://doi.org/10.1016/j.annonc.2020.08.2099>
 259. Di Dalmazi G, Berr CM, Fassnacht M, Beuschlein F, Reincke M. Adrenal function after adrenalectomy for subclinical hypercortisolism and Cushing's syndrome: a systematic review of the literature. *J Clin Endocrinol Metab.* 2014;99(8):2637-2645. <https://doi.org/10.1210/jc.2014-1401>
 260. Eller-Vainicher C, Morelli V, Salcuni AS, *et al.* Accuracy of several parameters of hypothalamic-pituitary-adrenal axis activity in predicting before surgery the metabolic effects of the removal of an adrenal incidentaloma. *Eur J Endocrinol.* 2010;163(6):925-935. <https://doi.org/10.1530/EJE-10-0602>
 261. Olsen H, Kjellbom A, Londahl M, Lindgren O. Suppressed ACTH is frequently unrelated to autonomous cortisol secretion in patients with adrenal incidentalomas. *J Clin Endocrinol Metab.* 2019;104(2):506-512. <https://doi.org/10.1210/jc.2018-01029>
 262. Bornstein SR, Allolio B, Arlt W, *et al.* Diagnosis and treatment of primary adrenal insufficiency: an endocrine society clinical practice guideline. *J Clin Endocrinol Metab.* 2016;101(2):364-389. <https://doi.org/10.1210/jc.2015-1710>
 263. He X, Findling JW, Auchus RJ. Glucocorticoid withdrawal syndrome following treatment of endogenous Cushing syndrome. *Pituitary.* 2022;25(3):393-403. <https://doi.org/10.1007/s11102-022-01218-y>
 264. Theiler-Schwetz V, Prete A. Glucocorticoid withdrawal syndrome: what to expect and how to manage. *Curr Opin Endocrinol Diabetes Obes.* 2023;30(3):167-174. <https://doi.org/10.1097/MED.0000000000000804>
 265. Terzolo M, Stigliano A, Chiodini I, *et al.* AME Position statement on adrenal incidentaloma. *Eur J Endocrinol.* 2011;164(6):851-870. <https://doi.org/10.1530/EJE-10-1147>
 266. Eisenhauer EA, Therasse P, Bogaerts J, *et al.* New response evaluation criteria in solid tumours: revised RECIST guideline (version 1.1). *Eur J Cancer.* 2009;45(2):228-247. <https://doi.org/10.1016/j.ejca.2008.10.026>
 267. Nogueira TM, Lirov R, Caoili EM, *et al.* Radiographic characteristics of adrenal masses preceding the diagnosis of adrenocortical

- cancer. *Horm Cancer*. 2015;6(4):176-181. <https://doi.org/10.1007/s12672-015-0225-2>
268. Ozsari L, Kutahyalioğlu M, Elsayes KM, *et al*. Preexisting adrenal masses in patients with adrenocortical carcinoma: clinical and radiological factors contributing to delayed diagnosis. *Endocrine*. 2015;51(2):351-359.
269. Speiser PW, Arlt W, Auchus RJ, *et al*. Congenital adrenal hyperplasia due to steroid 21-hydroxylase deficiency: an endocrine society clinical practice guideline. *J Clin Endocrinol Metab*. 2018;103(11):4043-4088. <https://doi.org/10.1210/jc.2018-01865>
270. Del Monte P, Bernasconi D, Bertolazzi L, *et al*. Increased 17 alpha-hydroxyprogesterone response to ACTH in silent adrenal adenoma: cause or effect? *Clin Endocrinol (Oxf)*. 1995;42(3):273-277. <https://doi.org/10.1111/j.1365-2265.1995.tb01875.x>
271. Patocs A, Toth M, Barta C, *et al*. Hormonal evaluation and mutation screening for steroid 21-hydroxylase deficiency in patients with unilateral and bilateral adrenal incidentalomas. *Eur J Endocrinol*. 2002;147:349-355. <https://doi.org/10.1530/eje.0.1470349>
272. Bouys L, Vaczlavik A, Jouinot A, *et al*. Identification of predictive criteria for pathogenic variants of primary bilateral macronodular adrenal hyperplasia (PBMAH) gene ARMC5 in 352 unselected patients. *Eur J Endocrinol*. 2022;187(1):123-134. <https://doi.org/10.1530/EJE-21-1032>
273. Bertherat J, Bourdeau I, Bouys L, Chasseloup F, Kamenicky P, Lacroix A. Clinical, pathophysiologic, genetic and therapeutic progress in primary bilateral macronodular adrenal hyperplasia. *Endocr Rev*. 2022:bnac034. <https://doi.org/10.1210/endo/rev/bnac034>
274. Debillon E, Velayoudom-Cephise FL, Salenave S, *et al*. Unilateral adrenalectomy as a first-line treatment of Cushing's syndrome in patients with primary bilateral macronodular adrenal hyperplasia. *J Clin Endocrinol Metab*. 2015;100(12):4417-4424. <https://doi.org/10.1210/jc.2015-2662>
275. Young WF, du Plessis H, Thompson GB, *et al*. The clinical conundrum of corticotropin-independent autonomous cortisol secretion in patients with bilateral adrenal masses. *World J Surg*. 2008;32(5):856-862. <https://doi.org/10.1007/s00268-007-9332-8>
276. Ueland GA, Methlie P, Jossang DE, *et al*. Adrenal venous sampling for assessment of autonomous cortisol secretion. *J Clin Endocrinol Metab*. 2018;103(12):4553-4560. <https://doi.org/10.1210/jc.2018-01198>
277. Johnson PC, Thompson SM, Adamo D, *et al*. Adrenal venous sampling for lateralization of cortisol hypersecretion in patients with bilateral adrenal masses. *Clin Endocrinol (Oxf)*. 2022;98(2):177-189.
278. Vassiliadi DA, Ntali G, Vicha E, Tsagarakis S. High prevalence of subclinical hypercortisolism in patients with bilateral adrenal incidentalomas: a challenge to management. *Clin Endocrinol (Oxf)*. 2011;74(4):438-444. <https://doi.org/10.1111/j.1365-2265.2010.03963.x>
279. Vassiliadi DA, Ntali G, Stratigou T, Adali M, Tsagarakis S. Aberrant cortisol responses to physiological stimuli in patients presenting with bilateral adrenal incidentalomas. *Endocrine*. 2011;40(3):437-444. <https://doi.org/10.1007/s12020-011-9490-1>
280. Bourdeau I, D'Amour P, Hamet P, Boutin JM, Lacroix A. Aberrant membrane hormone receptors in incidentally discovered bilateral macronodular adrenal hyperplasia with subclinical Cushing's syndrome. *J Clin Endocrinol Metab*. 2001;86:5534-5540.
281. Lacroix A, Bourdeau I, Lampron A, Mazzuco TL, Tremblay J, Hamet P. Aberrant G-protein coupled receptor expression in relation to adrenocortical overfunction. *Clin Endocrinol (Oxf)*. 2010;73:1-15.
282. Lacroix A, Baldacchino V, Bourdeau I, Hamet P, Tremblay J. Cushing's syndrome variants secondary to aberrant hormone receptors. *Trends Endocrinol Metab*. 2004;15(8):375-382. <https://doi.org/10.1016/j.tem.2004.08.007>
283. Lacroix A, Ndiaye N, Tremblay J, Hamet P. Ectopic and abnormal hormone receptors in adrenal Cushing's syndrome. *Endocr Rev*. 2001;22:75-110.
284. Libe R, Coste J, Guignat L, *et al*. Aberrant cortisol regulations in bilateral macronodular adrenal hyperplasia: a frequent finding in a prospective study of 32 patients with overt or subclinical Cushing's syndrome. *Eur J Endocrinol*. 2010;163(1):129-138. <https://doi.org/10.1530/EJE-10-0195>
285. Castinetti F, Taieb D, Henry JF, *et al*. MANAGEMENT OF ENDOCRINE DISEASE: outcome of adrenal sparing surgery in heritable pheochromocytoma. *Eur J Endocrinol*. 2015;174(1):R9-18.
286. Neumann HPH, Tsoy U, Bancos I, *et al*. Comparison of pheochromocytoma-specific morbidity and mortality among adults with bilateral pheochromocytomas undergoing total adrenalectomy vs cortical-sparing adrenalectomy. *JAMA Netw Open*. 2019;2(8):e198898. <https://doi.org/10.1001/jamanetworkopen.2019.8898>
287. Davenport C, Liew A, Doherty B, *et al*. The prevalence of adrenal incidentaloma in routine clinical practice. *Endocrine*. 2011;40(1):80-83. <https://doi.org/10.1007/s12020-011-9445-6>
288. Mannelli M, Dralle H, Lenders JW. Perioperative management of pheochromocytoma/paraganglioma: is there a state of the art? *Horm Metab Res*. 2012;44(5):373-378. <https://doi.org/10.1055/s-0032-1306275>
289. Stolk RF, Bakx C, Mulder J, Timmers HJ, Lenders JW. Is the excess cardiovascular morbidity in pheochromocytoma related to blood pressure or to catecholamines? *J Clin Endocrinol Metab*. 2013;98(3):1100-1106. <https://doi.org/10.1210/jc.2012-3669>
290. Kunikowska J, Matyskiel R, Toutouchi S, Grabowska-Derlatka L, Koperski L, Krolicki L. What parameters from 18F-FDG PET/CT are useful in evaluation of adrenal lesions? *Eur J Nucl Med Mol Imaging*. 2014;41(12):2273-2280. <https://doi.org/10.1007/s00259-014-2844-1>
291. Villar Del Moral JM, Munoz Perez N, Rodriguez Fernandez A, *et al*. [Diagnostic efficacy and discriminatory capacity of positron emission tomography combined with axial tomography of adrenal lesions]. *Cir Esp*. 2010;88(4):247-252. <https://doi.org/10.1016/j.ciresp.2010.07.007>